

Innovative Technique for Securing Autologous Melanocyte-keratinocyte Cell Transplant (MKCT) Suspension in Stable Vitiligo

Sharad Dattatray Mutalik, Yashashree Dhaval Rasal

Department of Dermatology, Maharashtra Medical Foundation's Joshi Hospital, Pune, Maharashtra, India

Abstract

Autologous cultured melanocyte transplantation is a safe and effective cellular regenerative surgical treatment modality for the lesions of stable vitiligo. Research continues to improve the efficacy of cell transplants by refining the procedure. The method of dressing used to secure the cell suspension over the treated site is vital in deciding the extent of repigmentation. The authors propose a simple modification in the dressing technique, which provides better graft adherence and results in uniform repigmentation, especially on challenging areas such as joints and other curved body surfaces.

Keywords: Cellular graft, innovation, surgery, vitiligo

PRACTICE POINTS

- Precise delivery of autologous MKCT suspension on a curved donor site is challenging.
- Cell suspension smeared on cut-to-size collagen-tulle composites ensures optimal and uniform delivery.
- Unique handling of cell suspensions ensures uniform repigmentation.

INTRODUCTION

Autologous MKCT is an effective cellular grafting technique that is used for the surgical treatment of stable lesions of vitiligo.^[1] The extent of repigmentation achieved with this technique depends on multiple factors, including the type and method of dressing used to secure the cell suspension over the treated site. The authors' goal is to describe an innovative technique of both delivering and securing the MKCT suspension over the recipient area.

BACKGROUND

In 1998, Olsson and Juhlin described the use of collagen dressing to cover the dermabraded recipient area after spreading of the resuspended cell suspension with a 1 ml

tuberculin syringe.^[2] [Figure 1]. The dressing was then finalized by using sterilized soft gauze and transparent adhesive dressing and fixed with nonwoven rayon back (micropore) surgical adhesive tape at the borders.^[3,4]

The cell suspension spreads evenly when the recipient anatomical site is flat, but it tends to seep out and get wasted when the anatomical site has a curve or a slope. This leads to a varied distribution of the transplanted melanocytes, resulting in incomplete and un-uniform repigmentation. To overcome this limitation, Van Geel *et al.* modified the technique by adding hyaluronic acid gel to the cell suspension, which prevents spillage to some extent, thereby achieving uniform spread of the harvested cells and increasing the adherence of the cells to the recipient site.^[3] We have further modified the dressing method for a more even spread and better securing of the cell suspension, especially over curved anatomical surfaces in view of achieving effective MKCT in stable vitiligo lesions.

Address for correspondence: Dr. Mutalik Sharad D,

Department of Dermatology, Maharashtra Medical Foundation's Joshi Hospital, Pune, Maharashtra, India.

E-mail: sharadmutalik.skindoctor@gmail.com

Access this article online

Quick Response Code:



Website:
www.jcasonline.com

DOI:
10.4103/JCAS.JCAS_143_20

This is an open access journal, and articles are distributed under the terms of the Creative Commons Attribution-NonCommercial-ShareAlike 4.0 License, which allows others to remix, tweak, and build upon the work non-commercially, as long as appropriate credit is given and the new creations are licensed under the identical terms.

For reprints contact: reprints@medknow.com

How to cite this article: Mutalik SD, Rasal YD. Innovative technique for securing autologous melanocyte-keratinocyte cell transplant (MKCT) suspension in stable vitiligo. *J Cutan Aesthet Surg* 2021;14:132-5.

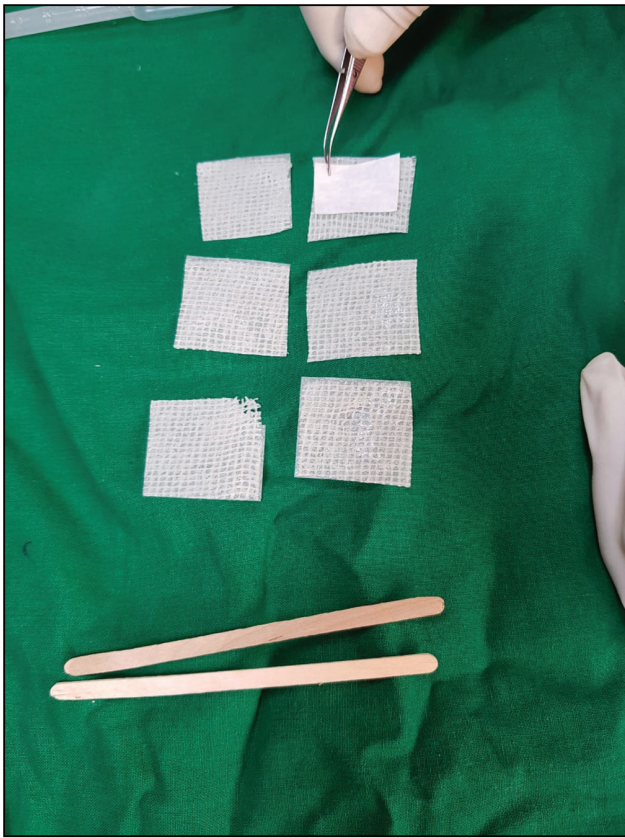


Figure 1: Conventional method of spreading the cell suspension

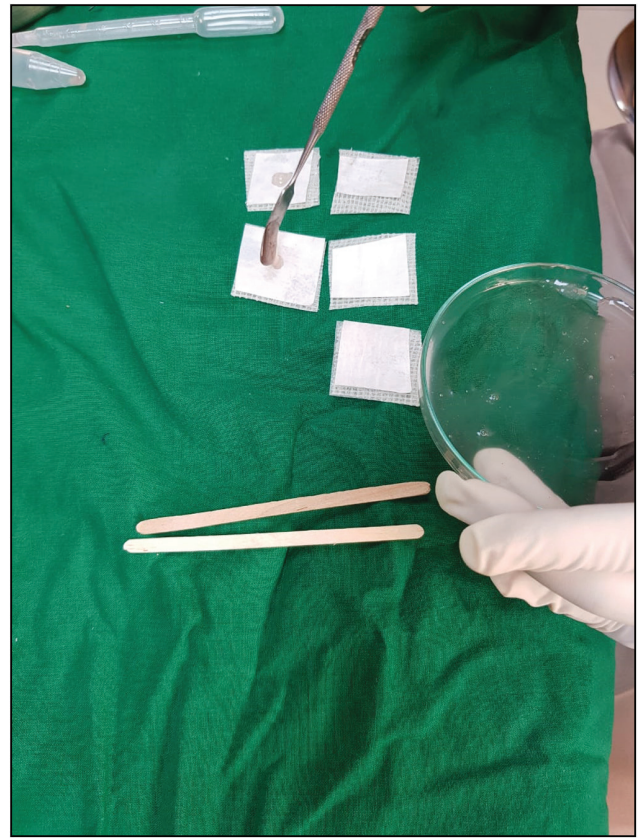


Figure 3: Cell suspension gel being spread over collagen-tulle composite with a spatula

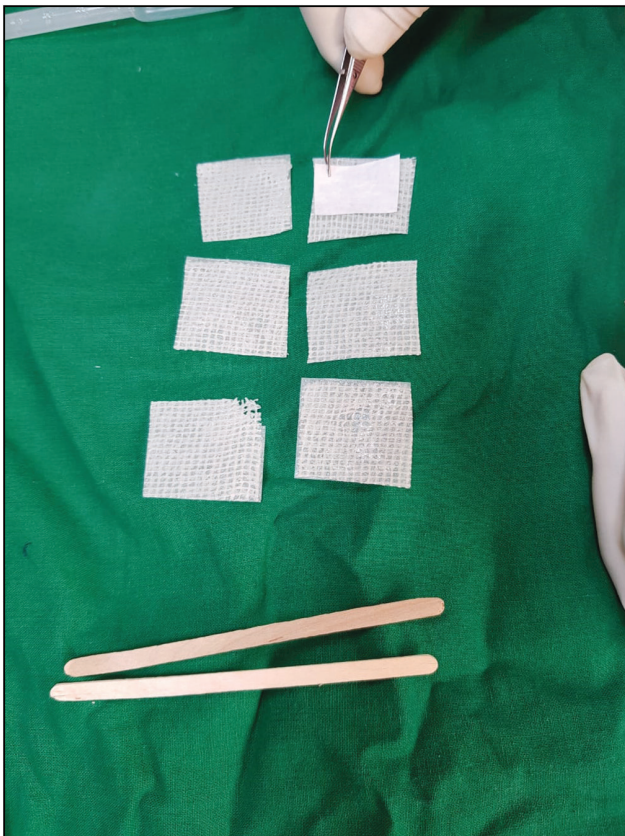


Figure 2: Dry collagen sheet cut to the shape placed over a chlorhexidine-impregnated tulle dressing

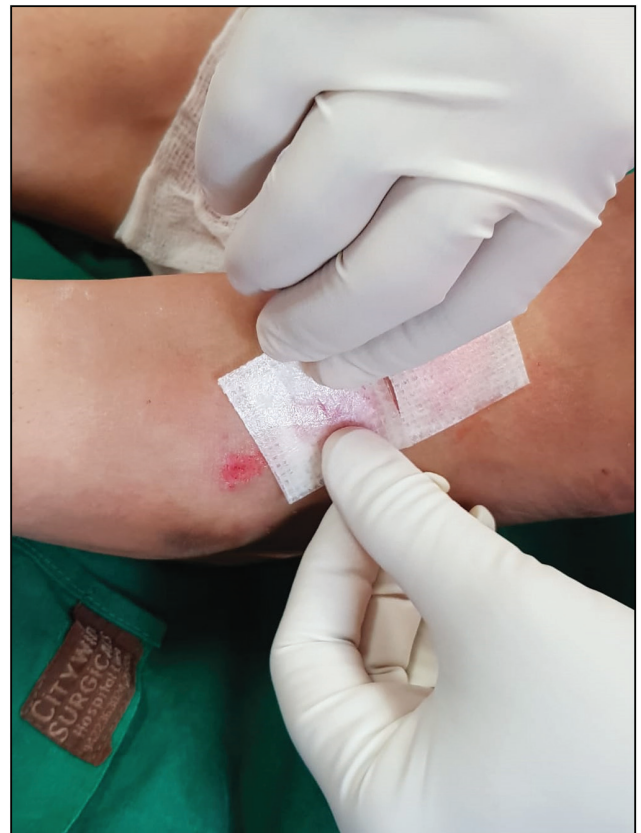

Figure 4: Facedown composite dressing over dermabraded recipient area.

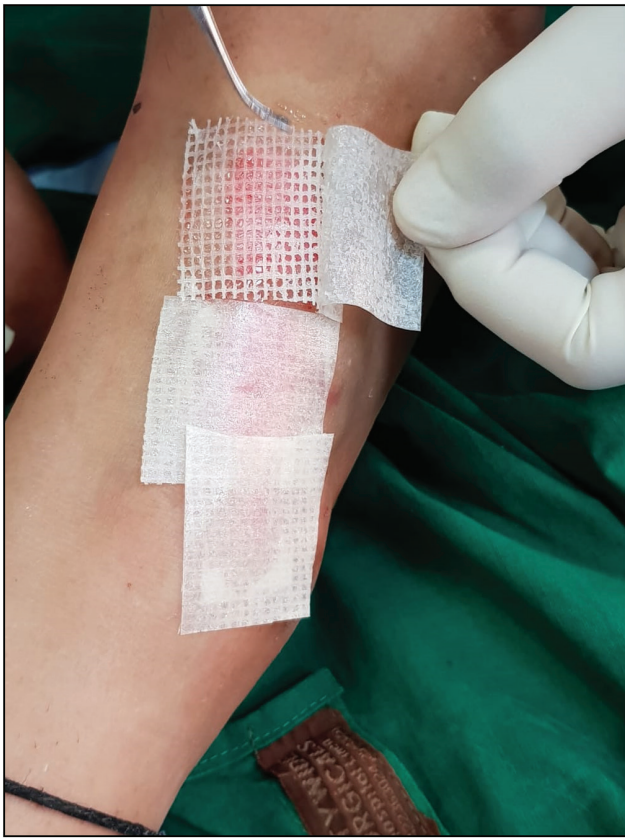

Figure 5: Carefully peeling off butter paper cover with a jeweller's forceps without disturbing the composite dressing

TECHNIQUE

The steps of the dressing method with the modification suggested by us are as follows:

- 1: The cell pellet containing melanocytes and keratinocytes is reconstituted in a viscous hyaluronic acid to create a semisolid gel.^[4]
- 2: A dry collagen sheet is placed over a chlorhexidine impregnated tulle dressing (Bactigras. Smith and nephew) cut to size and shape, such that it complements the recipient site [Figure 2].
- 3: The gel containing the cell suspension is spread over the collagen-tulle composite with a small spatula to form a film [Figure 3]. The entire procedure is carried out in a laminar flow chamber to prevent contamination.
- 4: This composite dressing smeared with the cellular suspension is then placed face down on the dermabraded/laser abraded raw recipient area [Figure 4].
- 5: Without disturbing the composite dressing, the butter-paper cover over the tulle is gently and carefully peeled off with a jeweller's forceps [Figure 5].

Further buttressing is achieved with sterile gauze pieces, secured with a transparent adhesive dressing (Tegaderm),

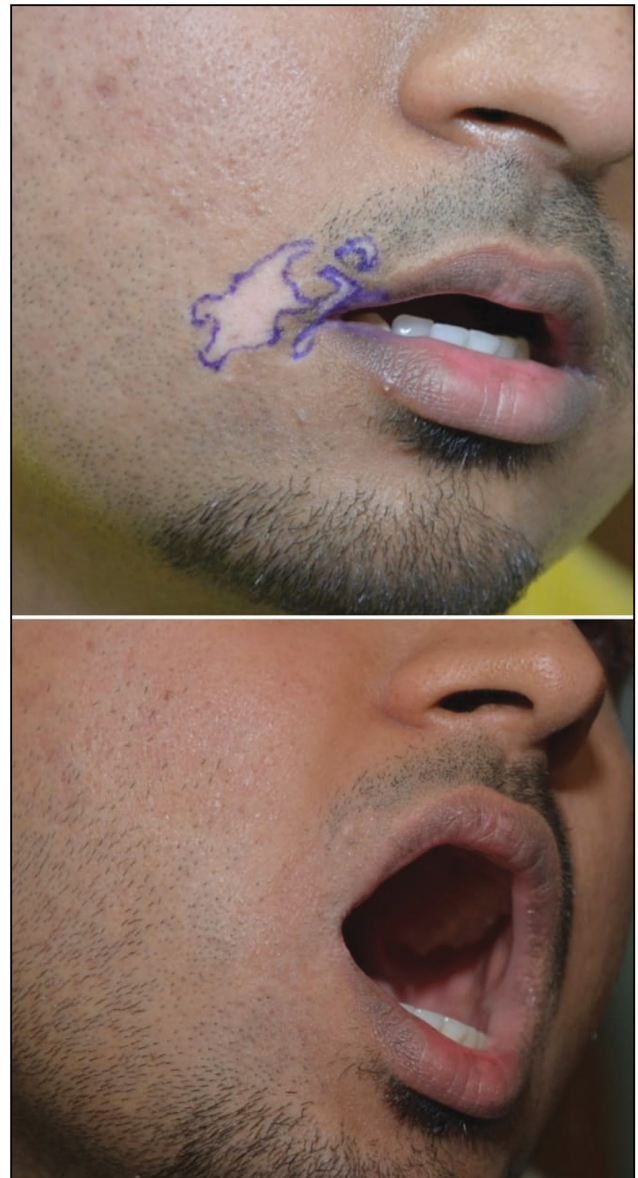

Figure 6: Complete and uniform repigmentation at a difficult anatomical site

which is then fixed with a micropore surgical tape at the borders. If the treated area is over the joints, it is reinforced with a compression bandage.

DISCUSSION

Since the application and implementation of this modification in the cellular transplantation and dressing technique, we have certainly experienced a better and easy handling of the cell suspension without any cell spillage and wastage. This simple method ensures meticulous and almost perfect MKCT, especially on curved body surfaces such as lips, jawline, breasts, and over the joints.

This innovative technique has helped us achieve uniform repigmentation of the vitiligo lesions with a complete blend and aesthetically pleasant outcomes [Figure 6], as compared with the results achieved with the conventional dressing technique used earlier. More number of prospective comparative studies will help establish our observations.

Declaration of patient consent

The authors certify that they have obtained all appropriate patient consent forms. In the form/ forms, the patient(s) has/ have given his/ her/ their consent for his/ her/ their images and other clinical information to be reported in the journal. The patients understand that their names and initials will not be published and due efforts will be made to conceal their identity, but anonymity cannot be guaranteed.

Financial support and sponsorship

Nil.

Conflicts of interest

There are no conflicts of interest.

REFERENCES

1. Gauthier Y, Surleve-Bazeille JE. Autologous grafting with noncultured melanocytes: A simplified method for treatment of depigmented lesions. *J Am Acad Dermatol* 1992;26:191-4.
2. Olsson MJ, Juhlin L. Leucoderma treated by transplantation of a basal cell layer enriched suspension. *Br J Dermatol* 1998;138:644-8.
3. van Geel N, Ongenaë K, De Mil M, Naeyaert JM. Modified technique of autologous noncultured epidermal cell transplantation for repigmenting vitiligo: A pilot study. *Dermatol Surg* 2001;27:873-6.
4. Mutalik S, Shah S, Sidwadkar V, Khoja M. Efficacy of cyclosporine after autologous noncultured melanocyte transplantation in localized stable vitiligo-A pilot, open label, comparative study. *Dermatol Surg* 2017;43:1339-47.