

# Autologous Mini Punch Grafting: An Experience of Using Motorized Power Punch in 10 Patients

**Background:** Autologous mini punch grafting (MPG) is a safe, effective and easy technique that can be performed on any site with minimal side effects and good cosmetic results. Large areas of stable generalised vitiligo require more grafts and are time consuming. Hence multiple sessions of surgery need to be scheduled. We share our experience of using motorised power punches to increase the speed of surgery in large areas of stable vitiligo in 10 patients. **Materials and Methods:** Ten patients in the age group of 12-55 years were treated with miniature punch grafting using power punches in single session on various sites. The power punches of 1-1.5 mm diameter were used to score donor and recipient sites, either of same or less than 0.2-0.3 mm size punches. The harvested grafts from donor site were then secured in the recipient beds and dressed. **Results:** The average number of grafts harvested per session was 125-185, the duration of surgery ranged from 45 to 90 minutes. Perigraft pigment spread was seen at 3 weeks. Complete repigmentation was observed in 3-4 months in eight patients. Cobble stoning was observed in one patient, and all donor sites healed well with superficial scarring. **Conclusion:** We conclude that autologous MPG with motorised power punches for stable vitiligo, especially on large areas including difficult sites can be performed with ease in comparatively lesser time in a single session, greatly benefiting the patients.

**KEYWORDS:** Mini punch grafting, motorised power punches, vitiligo surgery

## INTRODUCTION

Vitiligo surgery is indicated in stable recalcitrant or partially responsive vitiligo. The popular surgical methods among tissue grafts include Thin Thiersch's graft, Suction blister graft, punch grafting and mini punch grafting (MPG).<sup>[1,2]</sup> Autologous MPG is the easiest, effective and less expensive method of vitiligo surgery.<sup>[1]</sup> It is indicated in almost all sites especially in acral vitiligo involving palms, fingers, nipples and lips.<sup>[3]</sup> Punch grafting involves usage of 2-3 mm biopsy punches. Falabella reported use of smaller punches and hence the name MPG evolved.<sup>[4]</sup> The cosmetic result is good with MPG technique.<sup>[5]</sup> The time consumed in MPG using

punches of less than 1.5 mm is more when compared with punch grafting with 2-3 mm punches, more over the number of grafts required is also more with decrease in punch sizes. With the advent of motorised power punches the procedure can be done with more ease in lesser time to harvest more number of mini grafts (<1.5 mm) in a single session. We performed MPG in 10 patients of stable vitiligo on various sites with motorised power punch to see its efficacy and feasibility.

## MATERIALS AND METHODS

Ten patients, two males and eight females, in the age group of 12-55 years were treated with MPG using power punches. Three patients had focal, two had segmental, three had acral and two had generalised vitiligo. The duration of stability ranged from 1 to 2 years. None of them had koebnerisation. The different sites treated included face, lip, neck, hands, fingers, palm, waist, leg, ankle, areola and nipple. None of the patients had keloidal tendency. The grafting was planned in one session. The stainless steel power punches of 1, 1.2 and 1.5 diameter, loaded into hand piece of micro

Access this article online	
Quick Response Code: 	Website: <a href="http://www.jcasonline.com">www.jcasonline.com</a>
	DOI: 10.4103/0974-2077.129977

**BS Chandrashekar, C Madura, DV Varsha**

*CUTIS Academy of Cutaneous Sciences, Bangalore, Karnataka, India*

**Address for Correspondence:**

*Dr. Chandrashekar BS, # 5/1, 4th Main Road, MRCR Layout, Near Veeresh Theatre Behind Godrej Interio, Vijaynagar, Bangalore - 560 040, Karnataka, India.*

*E-mail: [cutisclinic@gmail.com](mailto:cutisclinic@gmail.com)*

motor designed by Tejco, Mumbai, were used for the procedure. Consent was obtained from all the patients. The procedure was performed under infiltrative local anaesthesia (1% xylocaine), donor area was from extensor aspect of thigh and post-auricular region. The micro motor was adjusted to a speed of 900-1200 rotation per minute, with 1:8 torque to speed ratio, power punch of a required size was loaded into the hand piece. The total number of grafts required was estimated based on size of the vitiligo patch to be treated, which ranged from 125 to 185 with an average of 155 per session. Both donor and recipient sites were simultaneously prepared and punch grafts were harvested by scoring skin up to upper dermis using power punches and then cutting the graft from the base by Castroviejo scissors from donor area. The grafts were handled with curved jeweler's forceps and transferred to a sterile bowl containing cold normal saline. Donor site homeostasis was achieved and covered with sterile gauze. In the recipient site, either same size punch or of 0.20-0.30 mm smaller punches were used to score the skin up to mid dermis about 3-5 mm apart. Punched vitiliginous skin was cut with Castroviejo scissors and discarded. The harvested grafts were then placed in the recipient chambers and were secured by firm pressure with moist gauze till complete homeostasis was achieved. The procedure is illustrated in Figure 1a-g. Tissue glue was used to fix the grafts and dressed in two layers with 1 cm<sup>2</sup> framycetin tulle pieces followed by sterile gauze and Dynaplast. The dressing was further stabilised with elastocrepe bandage in extremities and for lesions on joints, the area was immobilised with splints. At the recipient site, dressings were changed on day 10. Donor area was dressed with a layer of framycetin tulle followed by sterile gauze pad, which was removed on the 10<sup>th</sup> day. All the patients were started on topical immunomodulators and excimer lamp or NBUVB therapy 15<sup>th</sup> day onwards. The patients were assessed every 15 days for 3 months and once a month for the next 3 months.

## RESULTS

Out of 15 treated sites in 10 patients, the average numbers of grafts harvested were 125-185 (mean 155)

per session, the duration of surgery was 40-90 min. The transplanted tissue grafts changed from dark brown to black by the 10<sup>th</sup> day of the procedure. By the 15<sup>th</sup> day the scab dislodged to leave behind pink grafts, which turned to match the skin colour in 3-4 weeks. All the patients were started on phototherapy by end of 2 weeks. Pigment spread was observed in most of the grafts by 3-4 weeks and nearly completed by the end of 3-4 months [Figures 2-4]. All 15 sites showed good cosmetic colour match especially on lips, face and neck. Cobble stoning was observed in one patient. Graft rejection was noted in one patient on fingers. Graft take up was good on other sites. None of them developed donor site complications except for superficial scarring.

The demograph and results are depicted in Table 1.

## DISCUSSION

In 1972, Norman Orentreich first reported autograft repigmentation in humans by using 1 and 2 mm diameter autografts and observed 1 mm pigment spread. In 1983 Falabella used Miniature punches of 1.5 mm diameter and observed pigment spread of 25 mm.<sup>[6]</sup> Falabella made an important observation with regard to the relationship between the donor graft area and the area of surgical repigmentation and found that a 1 mm donor graft could originate a pigmented spot 25 times larger than its size.<sup>[4,7]</sup> Punch grafting is the easiest, fastest and least expensive method with high rate of success, with very few preventable or manageable side effects. Many studies have supported the high effectiveness of this procedure.<sup>[8-10]</sup> Cobble stoning, variegated appearance and colour mismatch, static graft, depigmentation of graft, perigraft halo and graft rejection are complications at recipient site and hypertrophic scars and depigmentation are complications at the donor site. Cobble stoning is the most common and can be prevented by using punches of less than 1.5 mm and about 1-1.2 mm on face and neck.<sup>[9-13]</sup> We observed that cobble stoning can be prevented by using same size punches at both donor and recipient sites or using 1.2 mm punch at donor site and 1 mm at recipient site on face and lips and

Table 1: Demographics and results

Age (years) /sex	Diagnosis	Site	No. of grafts per session	No of sessions	Perigraft pigmentation (weeks)	Side effects
13/F	Vitiligo vulgaris	Ankle and leg	125	1	3	Cobble stoning
40/F	Vitiligo vulgaris	Hands and fingers	180	1	5	None
13/F	Acral vitiligo	Ankle	150	1	3	None
49/F	Acral vitiligo	Hands and fingers	185	2	6	Static graft
24/F	Acral vitiligo	Palms and legs	165	2	3-4	Graft rejection
56/M	Mucosal vitiligo	Lips	85	1	3	None
22/F	Focal vitiligo	Bilateral Nipple and areola	170	2	3-4	None
24/F	Segmental vitiligo	Face	125	1	3	None
25/M	Segmental vitiligo	Neck	150	1	3	None
13/F	Focal vitiligo	Back	80	1	4	None

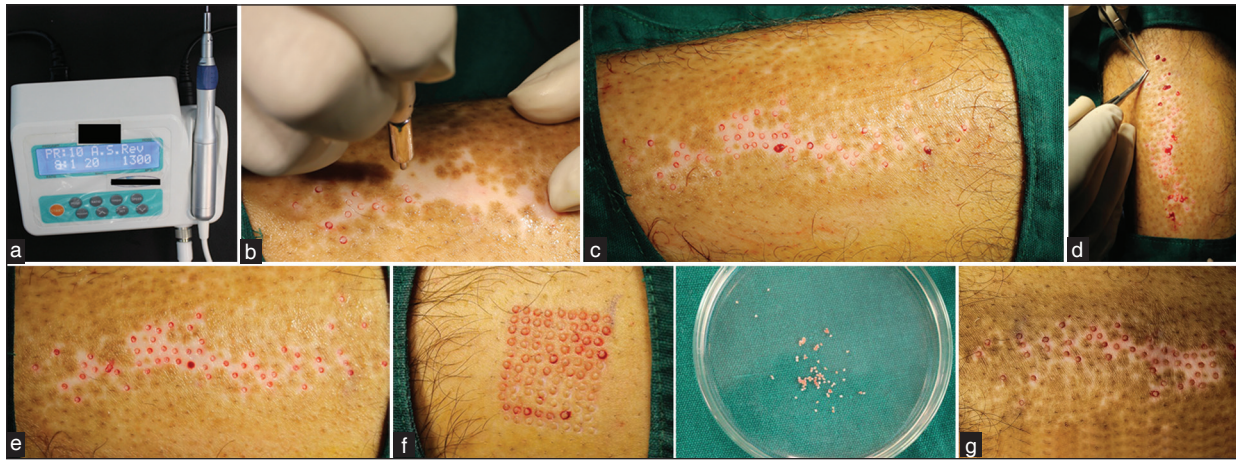


Figure 1: (a) The micromotor with stainless steel punch used to harvest grafts. (b) Scoring of recipient site with power punch. (c) Recipient site immediately after scoring with power punch. (d) Recipient scored grafts being cut with castrovejies scissors. (e) Shows recipient pits after removal of grafts. (f) Harvesting donor grafts. (g) Shows donor grafts being fixed at the recipient sites

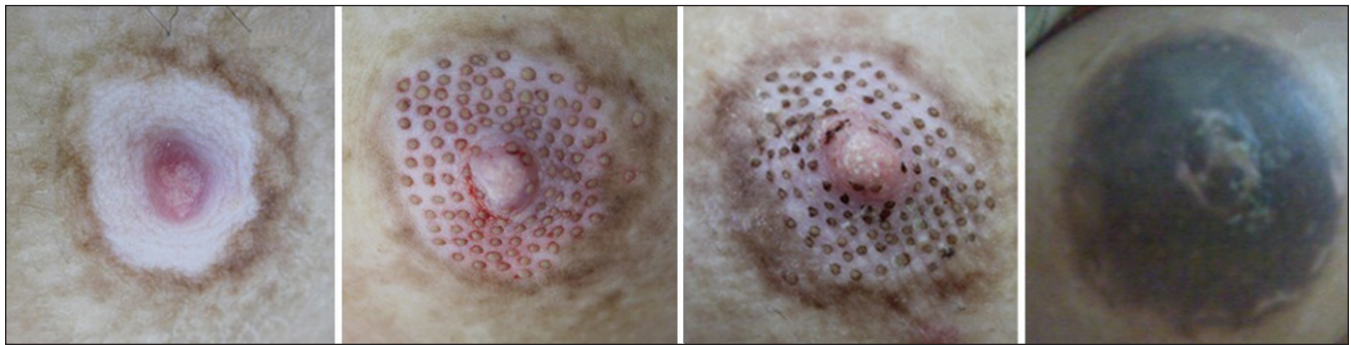


Figure 2: Shows pre-operative and post-operative (day 0, day 10 and 3<sup>rd</sup> month) photographs

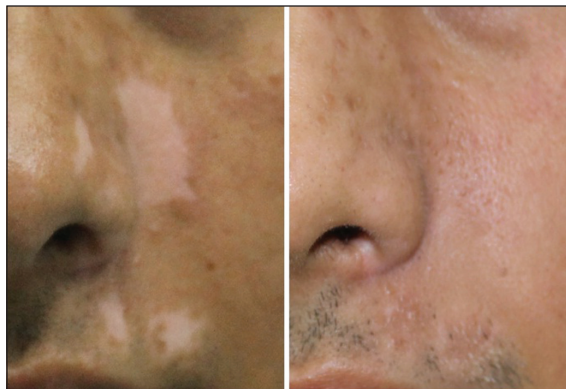

Figure 3: Shows pre-operative and post-operative (3<sup>rd</sup> month) photographs

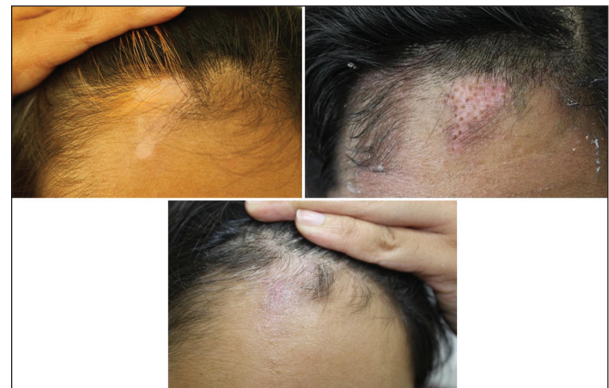

Figure 4: Shows pre-operative, post operative and follow up images

1.2 and 1.5 mm punches on recipient and donor sites, respectively, on the extremities.

In this study, 13 out of 15 sites (86.7%) repigmented with excellent cosmetic colour match. A complication was seen at one site (6.6%). Cobble stoning being the most common, as noticed in other MPG studies.<sup>[9,10]</sup> This can be prevented by making recipient pits slightly deeper. The grafts harvested were of required depth and

the depth assessment was easily done in the first 5-10 grafts, any thicker grafts in initial harvest was trimmed at base before transplant or by making the recipient punched out chamber beds deeper. Compared with our previous experience with manual MPG, the number of grafts harvested was more with motorised punches and were harvested with ease without surgeon's fatigability. Grafting was done in one session saving patient's time and consumables involved in each surgery and hence

the cost of surgery. The sequelae of graft healing were similar to manual MPG. The rapidly rotating motorised punches can easily score by just touching the mucosa/skin without exerting pressure. So it can be used in difficult sites like lip, nipple, palms and soles. We can also use a simple micromotor, which is used for dental procedures/dermabrasion with same ease.

In the donor area, close harvest was difficult to achieve in initial few surgeries. Thus power MPG requires some degree of expertise compared with manual MPG. The other disadvantages are the cost, need for sterilisation (chemical sterilisation) of reusable punches and replacement of motorised punch after every 2000 grafts.

## CONCLUSION

To conclude we say that motorised power punches enable the operator to harvest more grafts in a single session much faster than manual MPG. Thus, it avoids the Operator's Stress and also avoids pain in the operator's thumb, which is otherwise experienced with manual MPG. However, it needs surgical expertise in assessing the proper depth and also requires extra care for closer donor graft harvest.

## REFERENCES

1. Lahiri K. Evolution and evaluation of autologous mini punch grafting in vitiligo. *Indian J Dermatol* 2009;54:159-67.
2. Falabella R. Epidermal grafting: An original technique and its application in achromic and granulating areas. *Arch Dermatol* 1971;104:592-600.
3. Njoo MD, Westerhof W, Bos JD, Bossuyt PM. A systematic review of autologous transplantation methods in vitiligo. *Arch Dermatol* 1998;134:1543-9.
4. Falabella R. Repigmentation of segmental vitiligo by autologous mimigrafting. *J Am Acad Dermatol* 1983;9:514-21.
5. Singh KG, Bajaj AK. Autologous miniature skin punch grafting in vitiligo. *Indian J Dermatol Venereol Leprol* 1995;61:77-80.
6. Orentreich N, Selmanowitz VJ. Autograft repigmentation of leucoderma. *Arch Dermatol* 1972;105:784-6.
7. Falabella R. Repigmentation of leucoderma by minigrafts of normally pigmented, autologous skin. *J Dermatol Surg Oncol* 1978;4:916-8.
8. Savant SS. Autologous miniatures punch grafting in vitiligo. *Indian J Dermatol Venereol Leprol* 1992;58:310-4.
9. Lahiri K, Sengupta SR. Treatment of stable and recalcitrant depigmented skin conditions by autologous punch grafting. *Indian J Dermatol Venereol Leprol* 1997;63:11-4.
10. Malakar S, Dhar S. Treatment of stable and recalcitrant vitiligo by autologous miniature punch grafting: A prospective study of 1,000 patients. *Dermatology* 1999;198:133-9.
11. Falabella R. Surgical treatment of Vitiligo: Why, when and how. *J Eur Acad Dermatol Venereol* 2003;17:518-20
12. Lahiri K, Malakar S, Sarma N, Banerjee U. Repigmentation of vitiligo with punch grafting and narrow-band UV-B (311 nm) a prospective study. *Int J Dermatol* 2006;45:649-55.
13. Savant SS. Surgical therapy of vitiligo: Current status. *Indian J Dermatol Venereol Leprol* 2005;71:307-10.

**How to cite this article:** Chandrashekar BS, Madura C, Varsha DV. Autologous mini punch grafting: An experience of using motorized power punch in 10 patients. *J Cutan Aesthet Surg* 2014;7:42-5.  
**Source of Support:** Nil. **Conflict of Interest:** None declared.