

Chondroid Syringoma of the Philtral Dimple

Shirol Shidlingappa, Chandramohan Kudligi¹, Sharanabasav Choukimath², Shubha Nayak³, Srinivas Kodaganur³

Departments of Plastic Surgery, ²Pathology, ¹Dermatology and ³General Surgery, Karnataka Institute of Medical Sciences (KIMS), Hubli, Karnataka, India

Address for correspondence: Dr. Shirol Shidlingappa, Consultant Plastic and Cosmetic Surgeon, "Sampige" Plastic & Cosmetic Surgery Clinic, 1st Floor, Divate Complex, Club Road Hubli, 580028, Karnataka, India.
E-mail: ssshiirol@yahoo.co.uk

ABSTRACT

A chondroid syringoma (CS) is an exceedingly rare mixed tumor of the skin. These tumors are relatively common in the head and neck area. Occurrence of these tumors in the philtrum is rare, with only two documented cases in English literature to the best of our knowledge. This paper presents a case of CS of the philtral dimple with aesthetically excellent philtrum reconstruction.

KEYWORDS: Benign mixed skin tumor, chondroid syringoma (CS), philtral dimple, philtrum reconstruction

INTRODUCTION

A chondroid syringoma (CS) as initially described by Hirsch and Helwig^[1] is a cutaneous mixed tumor arising from the sweat glands and is composed of epithelial (sweat gland-like component) and mesenchymal components (myoepithelial cells embedded in a matrix with varying amounts of mucoid and cartilaginous material). It is relatively rare, with an incidence of 0.01-0.098% and with a male:female ratio of 3-5:1. It is mainly found involving the head and neck, though there is documentation of it involving the extremities, the scrotum, and the labia.^[1-3]

CASE REPORT

A 34-year-old male patient presented to us with a slow-growing but painful swelling over his philtral dimple for the past 6 months. On physical examination it was found to be a swelling of the size of 0.8 × 1.5 cm present on the philtral dimple, the skin over the swelling being shiny and erythematous [Figure 1a]. It was nontender, firm, and adherent to the skin without involvement of the underlying muscle or mucosa. We made a clinical diagnosis of a sebaceous cyst.

The fine-needle aspiration cytology (FNAC) of the lesion showed benign epithelial cells in groups, sheets, and microacini, and the background showed hemorrhage and proteinaceous material with a few fragments of myxoid stroma, suggesting a benign epithelial lesion – possibly a pleomorphic adenoma/CS [Figure 2a].

The lesion was excised along with the overlying skin of the philtral dimple, preserving the philtral columns, white roll, and Cupid's bow. There was no involvement of the orbicularis oris or oral mucosa. The philtrum was reconstructed with a postaural full-thickness skin graft [Figure 1b and c]. The postoperative esthetic outcome was excellent, with 100% graft take [Figure 1d].

The histopathology revealed stratified squamous epithelium with dermal tumor cells arranged in lobules, acinar pattern, and cords. Cells showed basophilic round to oval nuclei and moderate amount of cytoplasm with areas of chondromyxoid background; focal areas of cartilage differentiation were also seen. The features were suggestive of CS [Figure 2b].

This is an open access article distributed under the terms of the Creative Commons Attribution-NonCommercial-ShareAlike 3.0 License, which allows others to remix, tweak, and build upon the work non-commercially, as long as the author is credited and the new creations are licensed under the identical terms.

For reprints contact: reprints@medknow.com

How to cite this article: Shidlingappa S, Kudligi C, Choukimath S, Nayak S, Kodaganur S. Chondroid syringoma of the philtral dimple. *J Cutan Aesthet Surg* 2015;8:242-4.

Access this article online

Quick Response Code:



Website:
www.jcasonline.com

DOI:
10.4103/0974-2077.172207

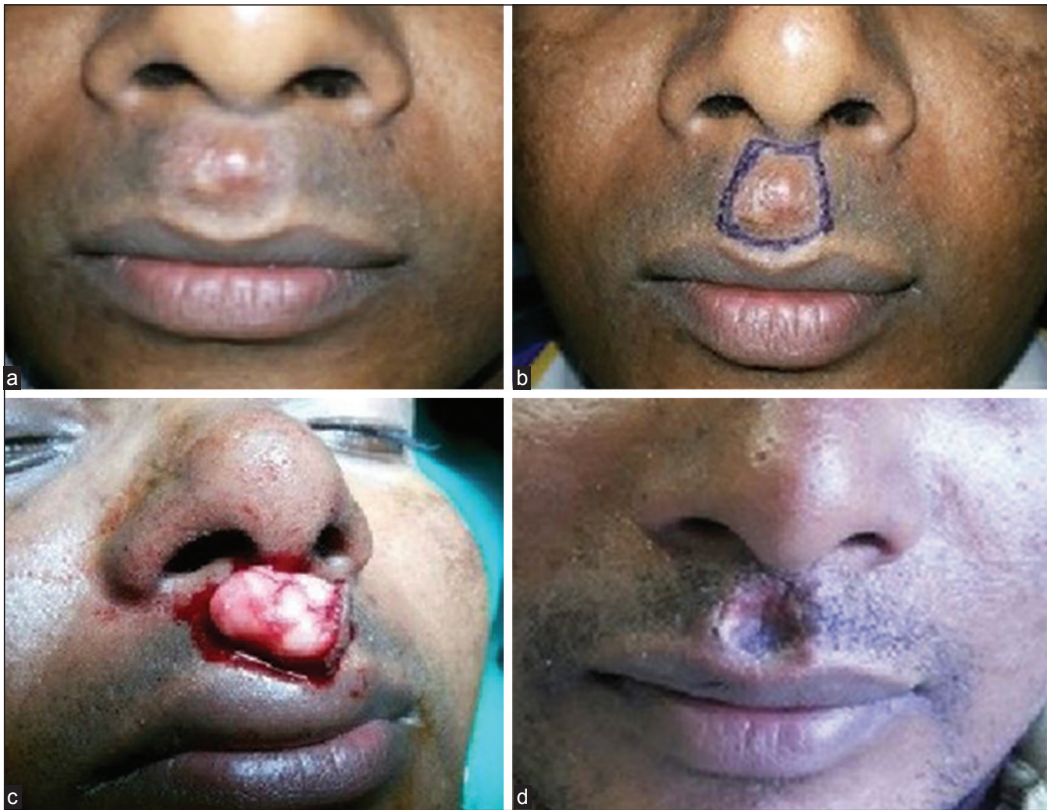

Figure 1: (a) Preoperative picture showing tumor of philtrum with involvement of skin (b) Planned excision of the tumor along with the skin (c) The excised tumor (d) Ten days postoperative picture of philtrum reconstructed with full-thickness skin graft

DISCUSSION

CS is a rare primary skin tumor with a reported incidence of <0.098%, affecting middle-aged to older men, and with a predilection to occur in the head and neck region and less commonly involving the extremities and genitalia. The CSs are either intradermal or subcutaneous tumors of sizes ranging 0.5-3 cm (though atypical larger lesions have been reported), are typically slow-growing and painless, show firm lobulated swelling, and are nonulcerating.^[2,3]

A CS is also referred to as cutaneous mixed tumor because it consists of both epithelial and myoepithelial cell types and may be considered a variant of myoepithelioma. There are two histological types of CS, i.e., apocrine and eccrine, apocrine being relatively more common. Histologically there are papillary infoldings of the cyst wall and glandular formations, with decapitation secretion representing apocrine elements with concurrent folliculosebaceous differentiation. Hirsch and Helwig described five histological criteria for the diagnosis of CS:

1. Nests of cuboidal or polygonal cells,
2. Interconnected tubuloalveolar structures lined by two or more rows of cuboidal epithelial cells,
3. Ductal structures lined by one or two rows of cuboidal cells,
4. Occasional keratinous cysts, and
5. A matrix of mixed chondroid and myxoid material.

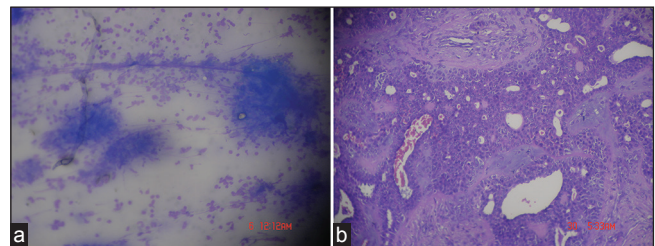


Figure 2: (a) Cytological picture of the lesion (b) Histopathological picture of the tumor

Some CSs display all five characteristics, whereas others only manifest a few. Very rarely can a benign CS turn malignant.^[4]

Clinically the tumor may be confused with many other skin lesions, such as a sebaceous cyst, a neurofibroma, a dermoid cyst, or a basal cell carcinoma (BCC), mandating accurate diagnosis of the lesion for optimum management.

Our literature search revealed only two documented cases of CS specifically involving the philtrum.^[5,6] The number of cases involving the philtral dimple may be higher because some of the upper lip CSs reported may involve the philtrum.

Management of lesions on the philtral dimple should always involve a plastic surgeon, as the philtrum is an esthetically significant unit of the upper lip. The philtrum is the central part of the upper lip. The philtral dimple/hollow forms the medial esthetic unit of the upper lip, bounded by the philtral columns. The white roll marks the junction of the skin of the upper lip and the vermilion border, which in the medial part forms the Cupid's bow. The vermilion itself is divided into the wet vermilion and dry vermilion, separated by a red line. The commissure is the angle of mouth, which is the point of meeting of the upper and lower lips [Figure 3]. The treatment involves complete excision of the lesion, preserving the philtral columns, white roll, Cupid's bow, and philtral dimple. The reconstruction can be done either with full-thickness graft (preauricular/postauricular) or a composite graft from the scalp (hair-bearing), or a full-thickness skin graft followed by hair transplant in men. A split-thickness skin graft would be a poor choice as the color and texture match would be poor. The esthetic unit was reconstructed with a full-thickness skin graft in our case, preserving the white roll and Cupid's bow. A good hemostasis, harvesting the full-thickness graft and exactly matching the template of the defect, and tie-over dressing would be important for good graft take. The patient did not want a hair-bearing philtrum as he felt he could camouflage the area with his long mustache. The authors argue that considering the benign nature of these lesions, reconstruction with good aesthetic outcome should be the priority.

CONCLUSION

Chondroid syringomas of the philtrum are rare apocrine tumors with masquerading clinical features. Clinical diagnosis is challenging and needs to be confirmed on histopathological examination.

What is new? Although two cases of CS of the philtrum have been reported in the literature, none of them featured extensive involvement of the skin, which would have required excision of the whole of the philtral skin. This article highlights the esthetic unit reconstruction of the philtral dimple with full-thickness skin graft and consequent excellent cosmetic outcome.

Declaration of Patient Consent

The authors certify that they have obtained all appropriate patient consent forms. In the form the




Figure 3: Surface anatomy and esthetic landmarks of upper lip
1. Philtral dimple/hollow (central esthetic unit of upper lip), 2. Philtral column, 3. Cupid's bow, 4. White roll, 5. Tubercle, 6. Dry vermilion, 7. Wet vermilion, 8. Oral commissure, 9. Lateral esthetic unit of upper lip, 10. Cheek esthetic unit

patient(s) has/have given his/her/their consent for his/her/their images and other clinical information to be reported in the journal. The patients understand that their names and initials will not be published and due efforts will be made to conceal their identity, but anonymity cannot be guaranteed.

Financial support and sponsorship

Nil.

Conflicts of interest

There are no conflicts of interest.

REFERENCES

1. Hirsch P, Helwig EB. Chondroid syringoma — Mixed tumour of skin, salivary gland type. *Arch Dermatol* 1961;84:835-47.
2. Yavuzer R, Başterzi Y, Sari A, Bir F, Sezer C. Chondroid syringoma: A diagnosis more frequent than expected. *Dermatol Surg* 2003;29: 179-81.
3. Bekerecioglu M, Tercan M, Karakok M, Atik B. Benign chondroid syringoma: A confusing clinical diagnosis. *Eur J Plast Surg* 2002;25: 316-8.
4. Constantinescu MB, Chan JB, Cassarino DS. Chondroid syringoma with tyrosine crystals: Case report and review of the literature. *Am J Dermatopathol* 2010;32:171-4.
5. Cha JH, Kim JW, Shin HK, Jung JH, Kim YH, Sun H. A case report of chondroid syringoma of philtrum. *J Korean Clef Palate-Craniofac Assoc* 2010;11:107-10.
6. Tokyol C, Aktepe F, Yavas BD, Yildiz H, Aycicek A. Chondroid syringoma: A case report. *Acta Cytol* 2010;54(Suppl):973-6.