

Erratum: Recurrent Adult Nasal Dermoid Cyst

In the article titled, “Recurrent Adult Nasal Dermoid Cyst” published in pages 151-152, issue 2, vol. 4 of Journal of Cutaneous and Aesthetic Surgery^[1], the section, “Declaration of Patient Consent” having the following information went missing due to technical errors:

“The authors certify that they have obtained all appropriate patient consent forms. In the form the patient(s) has/have given his/her/their consent for his/her/their images and other clinical information to be reported in the journal. The patients understand that their names and initials will not be published and due efforts will be made to conceal their identity, but anonymity cannot be guaranteed.”

The patient images in Figures 1 to 3 were not published correctly. The correct patient images in the article should be as follows:

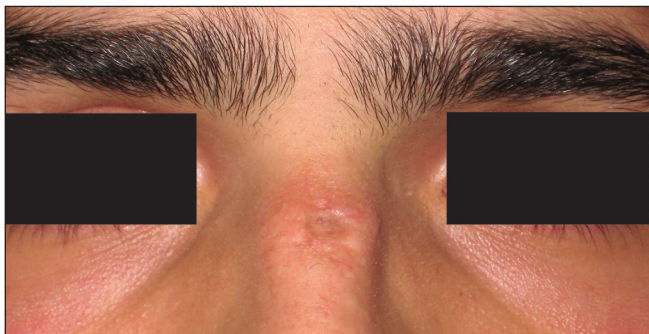

Figure 1: A 21-year-old male admitted to our clinic with a chronic exudative ulcer at the bridge of the nose

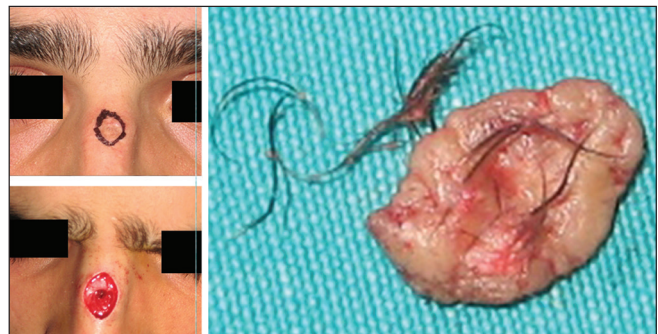


Figure 2: Intraoperative view of the operating site and lesion

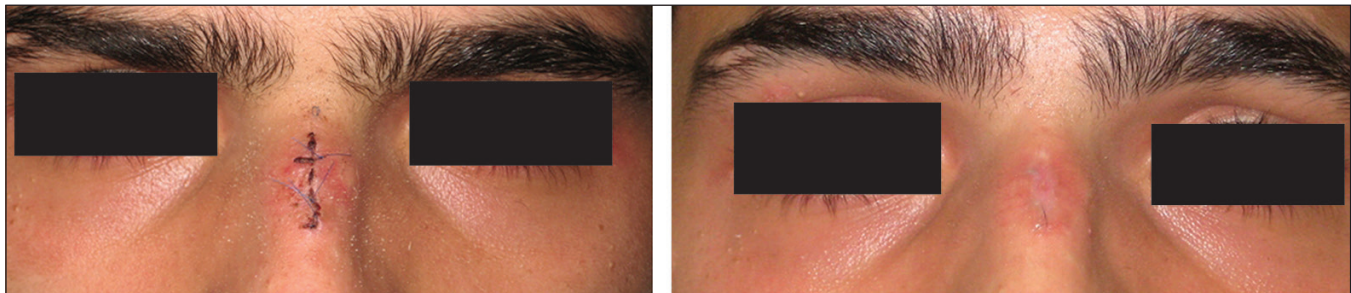


Figure 3: Early and late postoperative view of the operating site. Patient healed without problem

REFERENCE

1. Yildiz H, Cil Y, Simsek HA, Erginay T. Recurrent adult nasal dermoid cyst. *J Cutan Aesthet Surg* 2011;4:151-2.

DOI: 10.4103/0974-2077.204585