

An Uncommon Complication of Hair Transplant: A Crack in the “Slit”

Dear Editor,

We wish to report an uncommon complication that occurred while performing hair transplant surgery by the follicular unit transplantation (FUT) method. We routinely use stainless steel Kolkata slits^[1] for making slits for dissected hair follicle units to be implanted at the recipient site. However, we recently switched over to disposable Kolkata slits that closely resemble a keratome used by an ophthalmologist. The disposable Kolkata slit is much lighter, sharper, makes narrower slits, and causes lesser scarring than the stainless steel ones. It has a plastic handle and a small stainless steel blade of 1.2 mm width. After putting about more than 500 slits, suddenly a clicking sound was heard, and it was noticed that the blade of the slit had broken and more than half of the blade was retained in the scalp tissue. Immediately, the surrounding scalp tissue was explored with a 24 g needle and a jewelers' forceps, but

the retained piece could not be located. After about 20 min of futile search, a 1.5-cm incision was made and the loose areolar tissue of the involved scalp tissue was explored [Figure 1] and the broken piece of the blade was retrieved [Figure 2]. The incision was aesthetically sutured with 5-0 poliglecaprone-25 suture material. The area was then camouflaged by implanting hair follicles along the suture line. The patient was informed about the complication and was reassured. On follow-up, the scar along the suture line had healed well. However, there was an area of noticeable balding along the scar. After 6 months, this scar was covered by performing a localized follicular unit extraction (FUE) and the patient is subsequently doing fine.

The possible causes for the occurrence of this mishap could be the faulty quality of the instrument and inappropriate force applied while making slits.

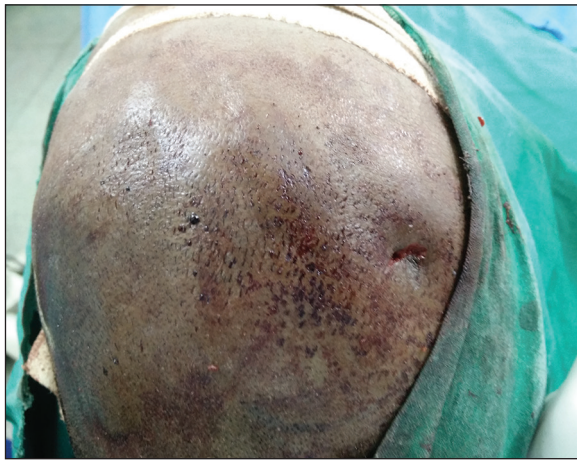


Figure 1: Incision made in the scalp in order to retrieve the broken piece of the blade

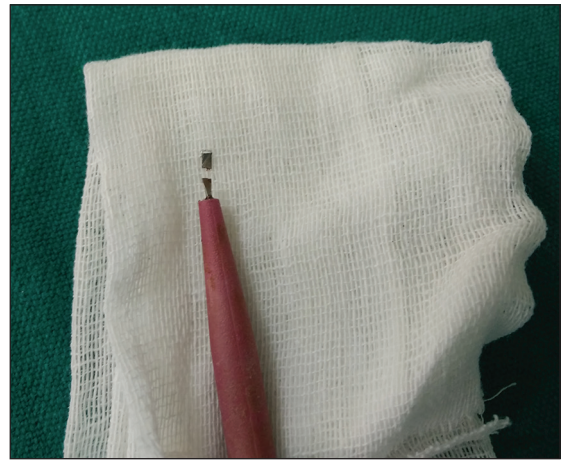

Figure 2: Broken distal piece of the blade and handle of the disposable Kolkata slit instrument

Disposable slits are less sturdy and one must be alert about choosing instruments of good quality. We haven't experienced a similar complication in the past nor have we found it in the data published.^[2] Thus, we wanted to report this to alert other hair transplant surgeons regarding the possibility of such a complication and the necessity of using high quality surgical instruments.

Financial support and sponsorship

Nil.

Conflicts of interest

There are no conflicts of interest.

**Govind S. Mittal, Sanjana Shivashankar,
Niranjana Raj, Holavanalli Veerabhadappa Nataraj**

*Department of Dermatology, Venereology and Leprosy,
Bangalore Medical College and Research Institute,
Bengaluru, Karnataka, India*

Address for correspondence: Dr. Govind S. Mittal,
#33, HB Samaja Road, Basavanagudi,
Bangalore - 560 004, Karnataka, India.
E-mail: govindmittal@gmail.com

REFERENCES

1. Kkanna M. Hair transplantation surgery. *Indian J Plast Surg* 2008;41(Suppl):S56-63.
2. Loganathan E, Sarvajnamurthy S, Gorur D, Suresh DH, Siddaraju MN, Narasimhan RT. Complications of hair restoration surgery: A retrospective analysis. *Int J Trichology* 2014;6:168-72.

This is an open access article distributed under the terms of the Creative Commons Attribution-NonCommercial-ShareAlike 3.0 License, which allows others to remix, tweak, and build upon the work non-commercially, as long as the author is credited and the new creations are licensed under the identical terms.

Access this article online	
Quick Response Code: 	Website: www.jcasonline.com
	DOI: 10.4103/0974-2077.172210

How to cite this article: Mittal GS, Shivashankar S, Raj N, Nataraj HV. An uncommon complication of hair transplant: A crack in the "slit". *J Cutan Aesthet Surg* 2015;8:247-8.