

***Tâche Noire*: A Classic Case Treated with Dual Freeze Cycles of Liquid Nitrogen Cryotherapy and Clasped Manoeuvre**

Dear Editor,

A *tâche noire* is a cutaneous hallmark occurring after a hard tick bite.^[1] We report an effective and safe method of tick removal using a specific manoeuvre along with

liquid nitrogen double-freeze cryotherapy.

A 24-year-old milkman presented with sudden onset of an itchy and painful black-crust lesion with a red

halo on his left upper scapular area [Figure 1a]. He had a history of handling dogs and cattle. However, he did not recollect any arthropod bite. Close examination showed irregular movement within the lesion, which revealed a tick holding onto the skin [Figure 1b].

After informed consent from the patient, we opted for cryotherapy. We applied 15 s of freezing directed from the lateral side of the tick, focusing on its mouthparts by tightly pinching the lesion [Figure 2].

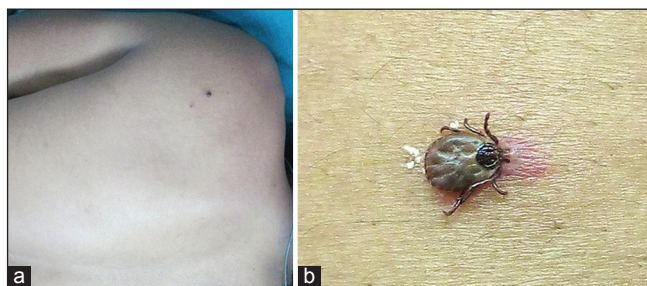


Figure 1: (a) Black, itchy, and slightly painful crusted eruption on the back of the patient (b) The tick was seen holding onto the skin

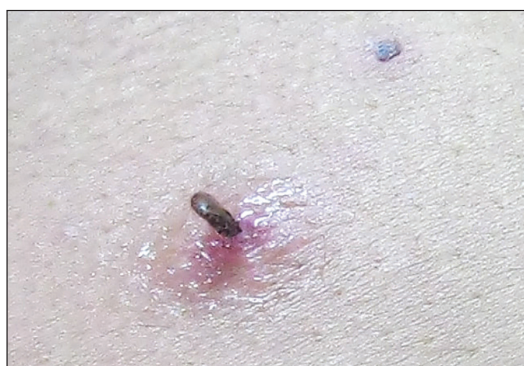

Figure 3: The previously flat and horizontally engorged tick moved into a vertical position after the first cycle of 15 s of freeze

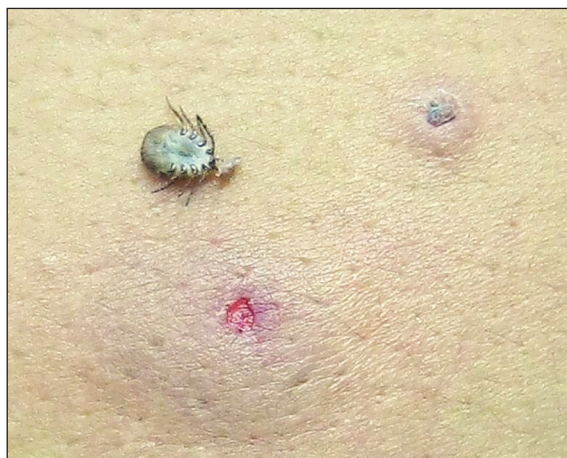

Figure 5: Prompt and complete removal of the tick after 3 min of the second cycle. The site became ulcerated

The previously flat and horizontally engorged tick became vertical [Figure 3]. This was due to transient spasmodic movements of its trunk posteriorly with its clasp not released anteriorly. After 3 min of thawing, we executed a second cycle of 15 s of freezing to the top position of the mouthparts [Figure 4]. After another 3 min of thawing, the tick spontaneously released its clasps and was removed *in toto*. The site became ulcerated [Figure 5]. Under 10× microscopy, we visualized its mouthparts and confirmed

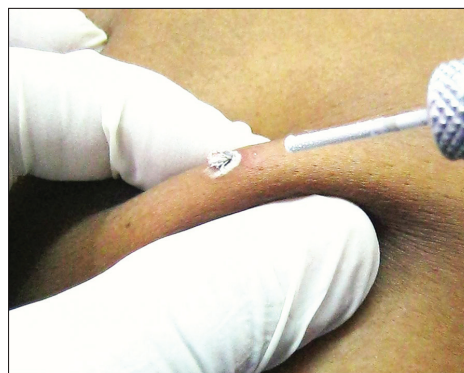

Figure 2: First freeze cycle after firmly clinching the base of skin with liquid nitrogen spray directed to clasped mouthparts of the tick at the site of tick adherence

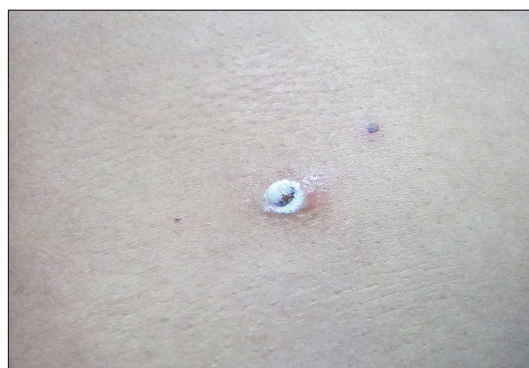

Figure 4: Freeze cycle repeated from the top

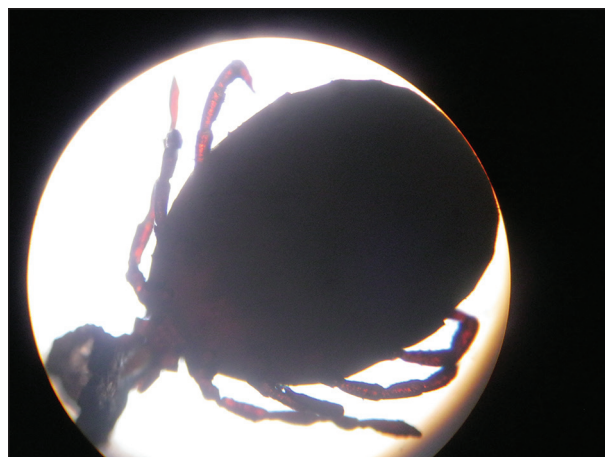

Figure 6: Tick mounted on light microscope (10×)

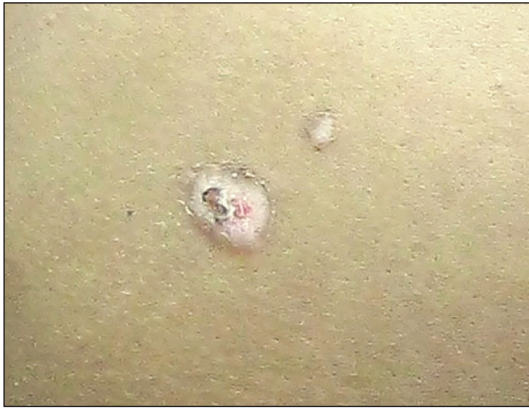

Figure 7: Appearance of the lesions 1 week after the procedure. The ulcer healed with transient depigmentation

that it was a hard tick [Figure 6]. We prescribed systemic azithromycin 500 mg twice daily for 3 days, systemic levocetirizine 5 mg daily for 7 days, and topical sodium fusidate ointment 2%. The site healed after 1 week [Figure 7].

Ticks belong to two major families, Ixodidae (hard tick) and Argasidae (soft tick).^[2] The hard tick bears a chitinous dorsal surface, and its mouthparts project forward with a toothed hypostome. *Tâche noire* is the cutaneous hallmark after a hard tick bite in 13-68% of patients with *Rickettsia conorii* infection, the pathogen causing Mediterranean spotted fever (African and Indian tick typhus).^[1] It is endemic throughout Africa, the Middle East, southern Europe, India, and southwestern Asia.^[3] It is important to remove the ticks as early as possible to reduce the chance of tick-borne infections. Ticks should not be arbitrarily pulled as twisting may break off its mouthparts, thereby leading to secretion of its infective body fluids.^[2] Unless promptly and carefully treated, complications such as tick paralysis, transmission of rickettsial infections with serious systemic involvement, subcutaneous hemorrhage, chronic ulceration, and leukocytoclastic vasculitis can arise.^[1,2] Modalities such as liquid paraffin, kerosene, petrol, iodine, ether, chloroform, and lignocaine jelly bear their respective drawbacks.^[3]

Pavlovic *et al.*^[4] and Lanschuetzer *et al.*^[5] reported tick removal by the application of liquid nitrogen with 20 s for a single freezing.

Based on our previous experience, the single-freeze method is inadequate in certain patients. A physical maneuver to pinch the chunk of skin on which the tick is attached may increase efficacy, more so than merely a distant cryospray. It may also prevent salivary dispersion of the tick into the deeper tissue, thus minimizing a risk of subsequent dissemination of tick-borne infection. We speculate that administration of cryotherapy may cause acute cryospasm

of mouthparts and body parts at the base of the clasped skin, which may help immediate release the clasp of the tick. To the best of our knowledge, our report is the third report on the utilization of cryotherapy in removing an attached tick and the first in the literature describing administration of double-freezing with a clasping maneuver.

We emphasize that cryotherapy is an easy, inexpensive method for prompt, safe, and complete removal of a tick by liquid nitrogen cryotherapy. Cryotherapy might prevent the subsequent risk of transmission of infections. However, close clinical monitoring is still highly recommended.

Financial support and sponsorship

Nil.

Conflicts of interest

There are no conflicts of interest.

Vijay Zawar, Gayatri Karad, Antonio Chuh¹

Department of Dermatology, Skin Diseases Centre, Nashik, Maharashtra, India, ¹School of Public Health, The Chinese University of Hong Kong and The Prince of Wales Hospital, Hong Kong
E-mail: vijayzawar@yahoo.com

REFERENCES

- Hay RF, Asriaans BM. Bacterial infections. In: Burns T, Breathnach S, Cox N, Griffiths C, editors. *Rook's Textbook of Dermatology*. 8th ed. UK: Blackwell Publishing Ltd; 2010. p. 30.72-30.74.
- Piesman J, Hojgaard A, Ullmann AJ, Dolan MC. Efficacy of an experimental azithromycin cream for prophylaxis of tick-transmitted Lyme disease spirochete infection in a murine model. *Antimicrob Agents Chemother* 2014;58:348-51.
- Needham GR. Evaluation of five popular methods for tick removal. *Pediatrics* 1985;75:997-1002.
- Pavlovic M, Alakeel A, Frances C. Tick removal with liquid nitrogen. *JAMA Dermatol* 2013;149:633.
- Lanschuetzer CM, Wieser M, Laimer M, Emberger M, Hintner H. Improving the removal of intact ticks. *Australas J Dermatol* 2003;44:301.

This is an open access article distributed under the terms of the Creative Commons Attribution-NonCommercial-ShareAlike 3.0 License, which allows others to remix, tweak, and build upon the work non-commercially, as long as the author is credited and the new creations are licensed under the identical terms.

Access this article online	
Quick Response Code: 	Website: www.jcasonline.com
	DOI: 10.4103/0974-2077.167290

How to cite this article: Zawar V, Karad G, Chuh A. *Tâche noire*: A classic case treated with dual freeze cycles of liquid nitrogen cryotherapy and clasped manoeuvre. *J Cutan Aesthet Surg* 2015;8:184-6.