

Aggressive Curettage-Cryosurgery for Human Papillomavirus-16 Associated Subungual Squamous Cell Carcinoma *In Situ*

Squamous cell carcinoma (SCC) *in situ* is an uncommon tumour of the nail unit. Mohs micrographic surgery or wide surgical excision are often the preferred treatments. As an alternative therapy two patients with human papillomavirus (HPV)-16 associated SCC *in situ* were treated by curettage-cryosurgery. After a careful curettage with different-sized curettes freezing with liquid nitrogen in a double freeze-thaw was performed. Both patients were treated successfully and healed completely within 3 months. No adverse events were observed during a follow-up of at least 5 years and no recurrences were noted. Curettage-cryosurgery might be a safe and non-resource-demanding alternative treatment for patients with subungual SCC *in situ*.

KEYWORDS: Curettage, cryosurgery, human papillomavirus, nail unit, squamous cell carcinoma *in situ*

INTRODUCTION

Squamous cell carcinoma (SCC) or SCC *in situ* are uncommon tumours of the peri- and subungual region. In this area SCCs *in situ* or Bowen’s disease (BD) are frequently found as hyperkeratotic red patches, verrucous, crusted or even ulcerated lesions in the periungual zone.^[1,2] However, often the malignancy also develops in the epithelium of the subungual tissue and there is a subsequent risk of invasive SCC, but metastases are rare.^[3] Well-known aetiologies are high-risk human papillomavirus (HPV) in about 90%,^[3] but ionizing or ultraviolet radiation, as well as arsenic could be a cause.

SCCs *in situ* of the nail unit are difficult to treat and even with wide surgical excisions or Mohs micrographic surgery (MMS) recurrences are not uncommon.^[1,4] Fifteen and five years ago, respectively, we have treated two patients with HPV-16 DNA-positive subungual SCC *in situ* with a combination of meticulous curettage and cryosurgery (CC) as an alternative to suggested digit amputation.

CASE REPORTS

Case 1

The first patient was a 58-year-old female with a subungual BD on a finger. She had previously been described as having a patient-specific HPV-16 strain in archival sample from intraepithelial neoplasia grade II on the portio of the uterine cervix in 1970 and subsequently in a subungual BD of the left ringfinger.^[5]

In 1995 an incomplete surgical excision of the subungual tumour was performed and therefore the surgeon suggested extirpation of the terminal phalanx. However, the patient, as being a pianist, wanted to try another form of treatment. In 1996 CC was carried out. After avulsion of the nail the tumour was found to cover most of the nail-bed. The patient had slight pain during the first few days after treatment but no analgesics were needed. Healing by secondary intention was without any complications. The final result was good with a well-functioning finger and with no recurrence after more than 5 years [Figure 1a-e].

Case 2

The second patient was a 57-year-old male. Since 2000 he had had a periungual lesion on his right index finger. The diagnosis was SCC *in situ* or BD, in which HPV-16 DNA was found. Two incomplete surgical excisions followed by grafting were performed. Photodynamic therapy (PDT) was also tried a couple of times with

Access this article online	
Quick Response Code: 	Website: www.jcasonline.com
	DOI: 10.4103/0974-2077.118417

Peter Nordin, Bo Clarence Stenquist
 Dermatology Clinic, Läkarhuset, Gothenburg, Sweden

Address for correspondence:
 Dr. Bo C Stenquist, Department of Dermatology and Venereology, Sahlgrenska University Hospital, SE-41345 Gothenburg Sweden. E-mail: bossstenquist@gmail.com

insufficient result. Instead of suggested amputation of the distal phalanx he was referred for CC in 2006. Also in this patient the curettage indicated that most of the nail-bed was infiltrated by the lesion. Post-operatively the wound had healed within 3 months with no pain at all and after 5 years, no recurrence was found. There was no history of HPV-associated genital lesions on the patient or his wife.

Cryosurgical technique

After a proximal digital nerve-block (mepivacaine 10 mg/ml) avulsion of the nail was performed. Then a thorough curettage using different-sized ring curettes (Thiemann, New York, USA) was carried out. At first a large curette (no. 3) was used to remove the bulk of the tumour, then a medium-sized one (no. 2), and finally a small curette (no. 1) to remove any extensions of the malignancy. In both our presented patients, before the avulsion of the nail, the tumour was just seen a few millimetres outside the nail as a discreet superficial slightly scaling lesion [Figure 1a]. However, after the meticulous curettage the lesion was found to infiltrate most of the nail-bed [Figure 1b]. The curettage was a heavy-handed one according to Strum and Leider^[6] implying a vigorous treatment not just a debulking procedure. When you perform the curettage you can “feel” that the soft tumour tissue separates from the firm and fresh basis. You continue the curettage until no more tissue can be separated. Of course there are small remnants of malignancy left [Figure 2] but these rests of tumour should be erased by the freezing. The curettage material was sent for histopathological examination, which confirmed the

diagnosis SCC *in situ*. A cotton stick dipped in a 50% iron chloride solution was used for haemostasis.

Then the freezing with liquid nitrogen (-196°C) in a double freeze-thaw cycle was carried out using a handheld Cry-Ac (Brymill Corp., USA). The spray tip, size B, was moved in circular motions over the treatment zone at about 1 cm distance until the lateral spread of freeze had reached a minimum of 5 mm outside the tumour border. The freezing was a maximal continuous spraying of liquid nitrogen for 20-25 s, the halo thaw time was more than 60 s, and the complete thaw time was about 4 min [Figure 1c]. Thermocouples were not employed. The treatments were performed at a single out-patient visit by the same physician (PN). The patients were examined 2 weeks after treatment [Figure 1d], then at 3, 6 [Figure 1e], and 12 months and yearly for at least 5 years.

DISCUSSION

SCCs *in situ* in the peri- and subungual region often grow insidiously and are difficult to delimit. Different types of treatment have been used. The most preferred treatment modalities are MMS^[4,7] and wide surgical excision.^[8] However, the recurrence rates are higher than expected when treated HPV-associated digital SCC or SCC *in situ*.^[3] Alternative therapies are PDT,^[9] radiotherapy,^[10] and cryosurgery,^[11,12] which have been more or less successful. In order to guarantee that all tumour strands have been removed and especially if bone involvement is found, amputation of the distal phalanx could be necessary. As alternative therapy we have used CC according to

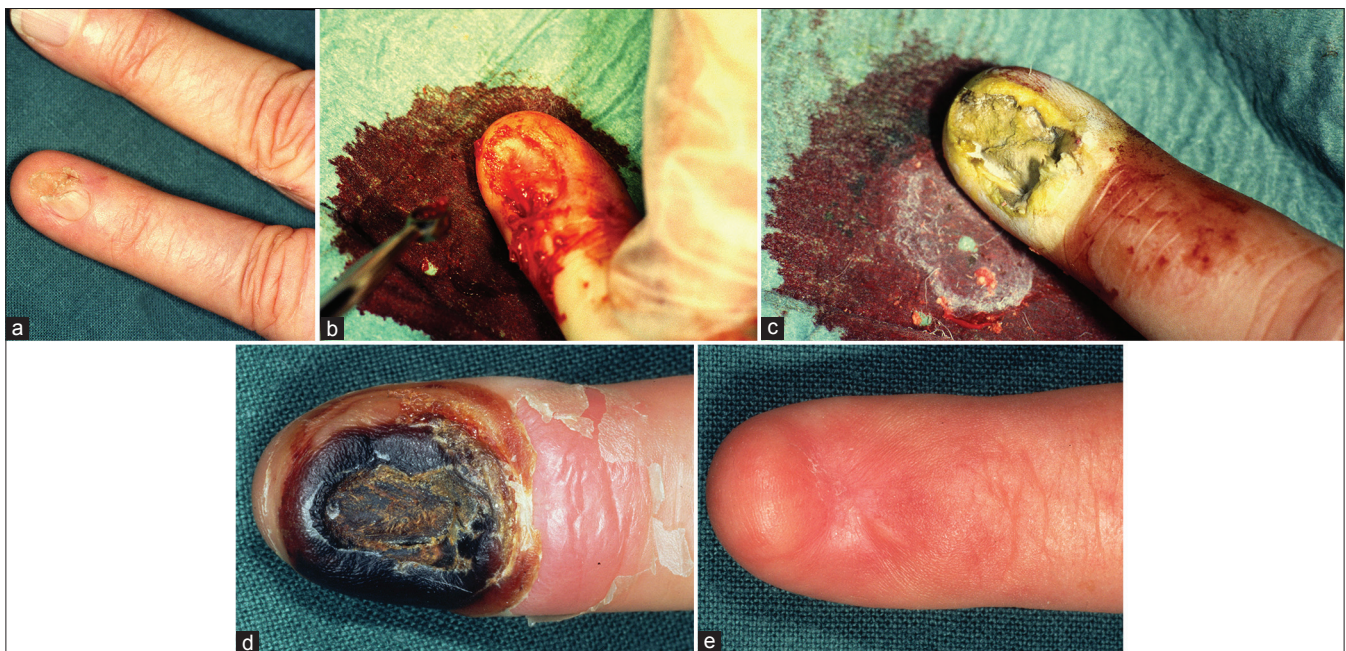


Figure 1: Treatment with curettage-cryosurgery of a subungual squamous cell carcinoma *in situ* of the left ring-finger – case 1 (a) Before treatment, (b) After a meticulous curettage the tumour was found to infiltrate most of the subungual zone, (c) The tumour area frozen with liquid nitrogen, (d) The result after 2 weeks, (e) The result obtained after 6 months

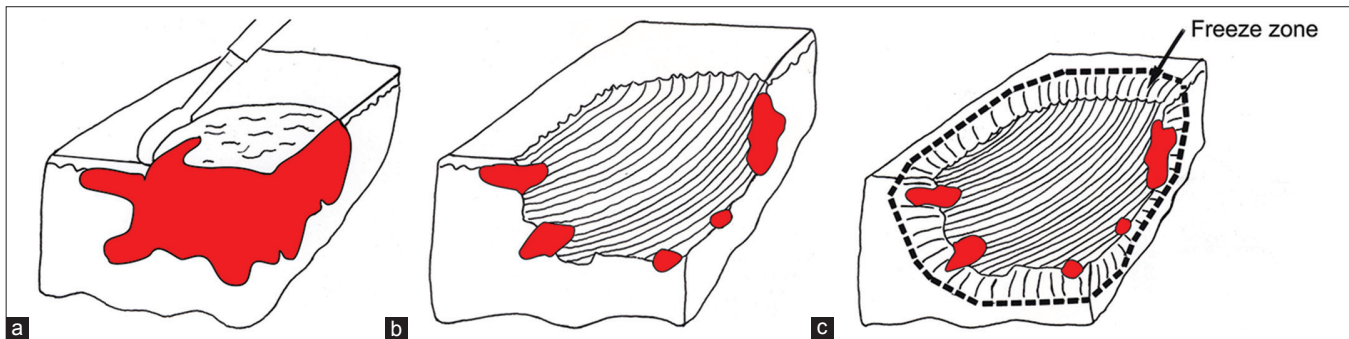


Figure 2: Schematic view of the cryosurgical technique for subungual SCC *in situ*, (a) Curettage, (b) After the curettage still some small nests of tumour remain, (c) A double freeze-thaw cycle with liquid nitrogen will erase any tumour extensions

a method established for non-morpheiform BCCs on the nose^[13] and on the ears^[14] to successfully eradicate subungual SCC *in situ* on fingers in two patients.

A very important part of this treatment is the meticulous curettage to delineate the tumour margins and remove the majority of the malignancy [Figure 2a and b]. The following freezing with liquid nitrogen in a double freeze-thaw cycle should eliminate any remaining tumour extensions and minimize the risk of recurrence [Figure 2c]. The treatment is performed during a finger block but no application of a bloodless field is necessary. The wound is left for healing by secondary intention and no grafting is needed. Both patients have been followed for at least 5 years with no recurrence.

Compared with extensive surgical excision and MMS, CC is a less resource-demanding out-patient procedure. A disadvantage with the powerful freezing is that the nail matrix will be destroyed, and thus no new nail will grow out. However, an advantage is that the risk of development of spicules could be minimized. This may be a problem after surgery.^[8]

Another post-surgical complication is that the extensor tendon may be injured as it inserts into the base of the distal phalanx.^[8] A great advantage with cryosurgery is that cellular tissue is more sensitive to cold than stromal tissue, implying that connective tissue, cartilage and bone, is affected but not damaged. Therefore the risk of injury of the extensor tendon as well as of the distal phalanx after the freezing would be minimal. Immunological response after the high freeze rate would also play a part in the healing process of these virus-associated tumours.^[15]

Curettage-cryosurgery may be an alternative conservative therapy for subungual SCC *in situ* when wide surgical excision is insufficient and resources for MMS are lacking. Moreover, the risk for tumour recurrence could be reduced if a thorough curettage for tumour demarcation followed by freezing with liquid nitrogen in a double freeze-thaw cycle is performed.

REFERENCES

1. Sau P, McMarlin SL, Sperling LC, Katz R. Bowen's disease of the nail bed and periungual area: A clinicopathological analysis of seven cases. *Arch Dermatol* 1994;130:204-9.
2. Dalle S, Depape L, Phan A, Balme B, Ronger-Savle S, Thomas L. Squamous cell carcinoma of the nail apparatus: Clinicopathological study of 35 cases. *Br J Dermatol* 2007;156:871-4.
3. Alam M, Caldwell JB, Eliezri YD. Human papillomavirus-associated digital squamous cell carcinoma: Literature review and report of 21 new cases. *J Am Acad Dermatol* 2003;48:385-93.
4. Zaiac MN, Weiss E. Mohs micrographic surgery of the nail unit and squamous cell carcinoma. *Dermatol Surg* 2001;27:246-51.
5. Forslund O, Nordin P, Andersson K, Stenquist B, Hansson BG. DNA analysis indicates patient-specific human papillomavirus type 16 strains in Bowen's disease on fingers and in archival samples from genital dysplasia. *Br J Dermatol* 1997;136:678-82.
6. Strum HM, Leider M. An editorial on curettage. *J Dermatol Surg Oncol* 1979;5:532-3.
7. de Berker DA, Dahl MG, Malmcolm AJ, Lawrence CM. Micrographic surgery for subungual squamous cell carcinoma. *Br J Plast Surg* 1996;49:414-9.
8. Jellinek NJ, Bauer JH. En bloc excision of the nail. *Dermatol Surg* 2011;36:1445-9.
9. Usmani N, Stables GI, Telfer NR, Stringer MR. Subungual Bowen's disease treated by topical aminolevulinic acid-photodynamic therapy. *J Am Acad Dermatol* 2005;53:S273-6.
10. Attiyeh FF, Shah J, Booher RJ, Knapper WH. Subungual squamous cell carcinoma. *JAMA* 1979;241:262-3.
11. Kuflik EG. Cryosurgery for skin cancer: 30-year experience and cure rates. *Dermatol Surg* 2004;30:297-300.
12. Santiago HR, Morales-Burgos A. Cryosurgery as adjuvant to Mohs micrographic surgery in the management of subungual squamous cell carcinoma. *Dermatol Surg* 2011;37:256-8.
13. Nordin P, Larkö O, Stenquist B. Five-year results of curettage-cryosurgery of selected large primary basal cell carcinomas on the nose: An alternative treatment in a geographical area underserved by Mohs' surgery. *Br J Dermatol* 1997;136:180-3.
14. Nordin P, Stenquist B. Five-year results of curettage-cryosurgery for 100 consecutive auricular non-melanoma skin cancers. *J Laryngol Oncol* 2002;116:893-8.
15. Sabel MS, Su G, Griffith KA, Chang AE. Rate of freeze alters the immunologic response after cryoablation of breast cancer. *Ann Surg Oncol* 2009;17:1187-93.

How to cite this article: Nordin P, Stenquist BC. Aggressive curettage-cryosurgery for human papillomavirus-16 associated subungual squamous cell carcinoma *in situ*. *J Cutan Aesthet Surg* 2013;6:155-7.

Source of Support: Nil. **Conflict of Interest:** None declared.