

Fractional Carbon Dioxide Laser in Combination with Topical Corticosteroid Application in Resistant Alopecia Areata: A Case Series

Imran Majid, Shazia Jeelani¹, Saheer Imran

CUTIS Institute of Dermatology, Srinagar, ¹Department of Dermatology, Jammu and Kashmir Health Services, Jammu and Kashmir, India

Abstract

Introduction: Intradermal steroid injections are used as treatment option in resistant alopecia areata. However, it is difficult and quite painful to treat large areas of alopecia with this modality. **Objective:** To assess the efficacy and safety profile of a combination of fractional carbon dioxide (CO₂) treatment followed by topical corticosteroid application in resistant alopecia areata. **Materials and Methods:** Ten cases of resistant alopecia areata who had not responded to multiple treatment modalities were treated with fractional CO₂ laser followed by topical application of triamcinolone spray (10mg/mL) on the resistant lesions. Patients received 4–8 sessions that were repeated at an interval of 3–4 weeks. Response to treatment was assessed on a quartile physician assessment scale and labeled as excellent (>75% regrowth), good (50%–75% regrowth), fair (26%–50% response), and poor (<25% regrowth). **Results:** Eight of these ten cases completed the treatment process. Seven of these eight patients had complete recovery of the area treated. One patient however did not show good response even after four sessions. No significant adverse effects were noted in any of the patients. **Conclusion:** Fractional CO₂ laser in combination with topical triamcinolone can prove to be an effective treatment option in resistant alopecia areata.

Keywords: Alopecia areata, fractional laser, fractional laser-assisted drug delivery, resistant alopecia, triamcinolone

INTRODUCTION

Alopecia areata is a chronic inflammatory disorder resulting in non-cicatricial hair loss. It can affect hair over scalp, beard, and eyebrows/eyelashes or can even be generalized. It affects both sexes and all age groups. Etiology of alopecia areata is unknown, but it is regarded as an autoimmune disorder with genetic predisposition.^[1] Prognosis of alopecia areata is variable in some patients having spontaneous regrowth after some time, whereas in some others, it may be progressive with poor prognosis. Poor prognostic factors include childhood onset, extensive disease, ophiasis pattern, and nail abnormalities.^[1-3] Various treatment modalities that have been suggested are corticosteroids (topical or intralesional), contact sensitizers, topical minoxidil, topical tacrolimus, and topical vitamin D analogs. For recalcitrant cases, psoralen with ultraviolet A light, oral cyclosporine, oral

corticosteroids, and other immunosuppressants have been used.^[2,3] Use of lasers/light systems to stimulate hair regrowth has been known for years.^[4] To the best of our knowledge, only a single report of the successful use of fractional laser therapy as monotherapy for alopecia areata is available.^[5] Dermal heat produced because of fractional laser therapy is presumed to stimulate the hair regrowth. In addition to their direct therapeutic effect, fractional lasers also act through transepidermal drug delivery (TED) of the topical steroid into the hair follicle. This property of fractional lasers is popularly known as “laser-assisted drug delivery,” which has found use in many dermatological disorders such as burn scars,^[6] skin

Address for correspondence: Dr. Imran Majid,
CUTIS Institute of Dermatology, Hyderpora, Srinagar,
Kashmir 190014, India.
E-mail: imran54@yahoo.com

This is an open access journal, and articles are distributed under the terms of the Creative Commons Attribution-NonCommercial-ShareAlike 4.0 License, which allows others to remix, tweak, and build upon the work non-commercially, as long as appropriate credit is given and the new creations are licensed under the identical terms.

For reprints contact: reprints@medknow.com

How to cite this article: Majid I, Jeelani S, Imran S. Fractional carbon dioxide laser in combination with topical corticosteroid application in resistant alopecia areata: A case series. J Cutan Aesthet Surg 2018;11:217-21.

Access this article online

Quick Response Code:



Website:
www.jcasonline.com

DOI:
10.4103/JCAS.JCAS_96_18

malignancies, and even inflammatory skin diseases such as lichen planus.^[7] Fractional laser-assisted drug delivery of corticosteroids for resistant alopecia areata is a new concept in dermatological therapy.

MATERIALS AND METHODS

We present a case series of 10 patients with the diagnosis of resistant alopecia areata of the scalp, beard, and eyebrow area, who were treated with fractional CO₂ laser and topical steroid combination. The diagnosis of alopecia areata was made clinically, and the disease was termed as resistant only when it had not responded to at least two different modes of treatment [Table 1]. After inclusion into the study, the patients were thoroughly assessed for any associated autoimmune and endocrine disorders with relevant history, physical examination, and investigations wherever indicated. In addition to clinical evaluation, digital photographs (Nikon D5100, Japan, 16.2 MP) were taken at baseline and at each follow-up visit to document clinical response. Written consent was obtained from all the patients and in case of minors, from their parents. Response to treatment was assessed by clinical examination and repeat digital photography at each treatment session. The degree of clinical improvement was evaluated according to a quartile scale of improvement and termed as excellent if >75% regrowth was observed. Response to treatment was labeled as good if 50%–75% regrowth was observed, whereas 25%–49% and <25% regrowth was labeled as fair and poor, respectively.^[6]

PROCEDURE

Topical anesthesia in the form of a eutectic mixture of lignocaine and prilocaine (Dolocaine, Cadila Pharmaceuticals, Mumbai, India) was applied over the areas to be treated. After 45–60 min, the area was cleaned with 70% ethanol and later with normal saline. Fractional CO₂ laser (eCO₂ fractional CO₂ laser from Lutronics,

Korea) was used in ablative mode with 120 µm tip. The procedure was carried out at a fluence of 50–60 mJ/cm² and density of 100 microthermal zones (MTZ)/cm². These parameters were selected to facilitate the transepidermal delivery of the topical steroid into the dermis. A single pass of laser treatment was given to the affected area, and immediately after the treatment, triamcinolone solution (10 mg/mL) was sprayed on the treated area and spread evenly using a cotton-tipped bud. Treatment sessions were repeated every 3 weeks for a maximum of eight sessions or until complete hair regrowth was achieved. Treatment sessions were discontinued if no significant therapeutic response was observed at the end of three sessions. The patients were given no topical treatments in between the laser sessions.

RESULTS

Of the ten patients, only eight completed the treatment protocol of a minimum of 3 sessions [Table 1]. Remaining two patients did not turn up after the first session of laser treatment. These two patients were contacted and they did not wish to continue with the treatment method because of no response after the first session. Six of these eight cases had involvement of scalp, whereas one each had disease limited to beard and eyebrows, respectively. Mean duration of disease in these eight patients was 7 years.

Of the eight cases who completed at least three sessions of combination treatment, seven patients showed excellent response to the treatment in the form of at least 75% regrowth [Figures 1–3]. In fact, three of these eight cases showed complete or near complete regrowth of hair on the treated areas within the study period. Onset of hair regrowth was usually reported after the second session of combination treatment in most of the responders.

In one patient who had only the beard area involved, we treated the left half of the face first and kept the right half as control to observe any comparative difference on the

Table 1: Patient data showing site of involvement and past treatments used

S. no.	Age (years)	Sex	Duration (years)	Previous treatments	No. of sessions	Sites treated	Response (%)
1	18	M	3	Topical CS, oral CS, topical MX	1	Occipital—ophiasis	NA
2	29	F	8	Oral CS, oral azathioprine, topical CS	8	Scalp—extensive	95
3	29	M	6	Oral CS, azathioprine, sulfasalazine	4	Scalp—patchy	75
4	48	F	5	Oral CS, topical MX	3	Eyebrows	75
5	32	M	10	Oral CS, sulfasalazine, azathioprine, methotrexate	9	Face, eyebrows, neck, scalp—ophiasis	90
6	27	M	6	Oral CS, topical CS	1	Beard	NA
7	11	F	3	Oral CS, topical MX	4	Scalp—patchy	90
8	43	M	4	Oral CS, azathioprine, sulfasalazine	5	Beard, occipital—ophiasis, patchy	85
9	27	F	15	Oral CS, topical MX	4	Scalp (frontal)—extensive	15
10	25	M	5	Oral CS, topical CS	4	Beard	90

M = male, F = female, CS = corticosteroids, MX = minoxidil, NA = not available

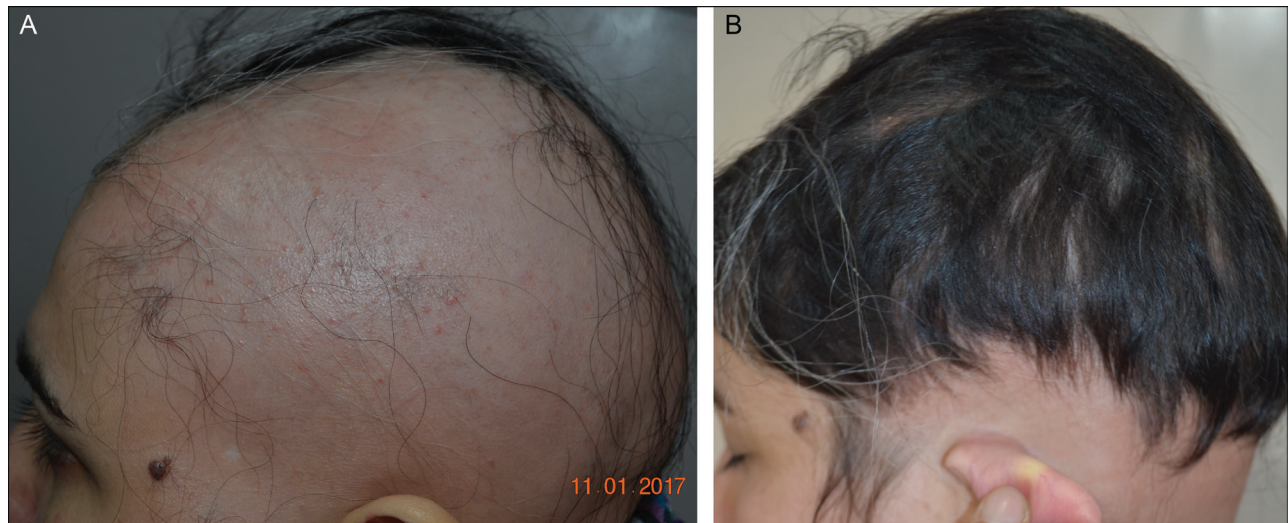


Figure 1: (A) Resistant alopecia subtotalis in a 25-year-old female. (B) Response to five sessions of fractional laser with triamcinolone spray

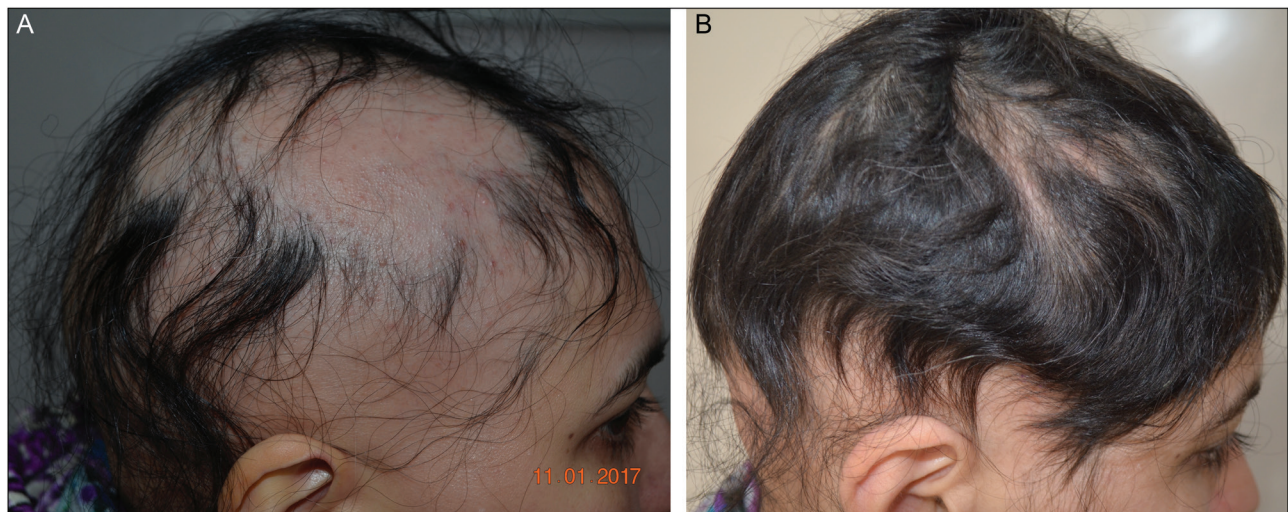


Figure 2: (A) Same patient as in Figure 1 on the right side. (B) Response after treatment with fractional laser and triamcinolone spray

two sides. In this patient, therapeutic benefit was noticed only on the left side of the face first, whereas lesions on the right side remained the same. Later on, the right side of the face was treated as well.

No significant adverse effects were noted in any of the treated patients, and all patients tolerated the procedure well. The youngest girl patient aged 11 years could also tolerate the laser procedure without any significant discomfort, and no sedation or other medications were needed in this patient during the procedure. None of the patients showed any evidence of skin atrophy in the treated area during the follow-up period.

DISCUSSION

TED is a technique to optimize the penetration of drugs into the target tissue and this can be achieved by chemical, mechanical, and physical methods. Use of lasers for TED was first described in 1987 by using an ablative

non-fractional device.^[8] Fractional lasers for TED was introduced by Manstein *et al.*^[9] in 2004.

The generation of MTZ by fractional lasers provides the channels for a uniform and controlled delivery of drugs. As the channels are distributed throughout the target area in a uniform manner, the drug deposition also becomes uniform. Fractional lasers can penetrate up to 2–3 mm into the dermis, depositing thermal energy where the dermal papilla is, which is where the capillaries surround the hair germ cells.^[10] It has been suggested that fractional laser could act by inducing T cell apoptosis, increasing blood flow, and promoting telogen to anagen transitions.^[5,10,11] Recently, a murine model study showed anagen induction related to Wnt/ β -catenin pathway after fractional laser treatment, resulting in hair regrowth and increased proportion of anagen hairs.^[12] The direct therapeutic effect of fractional laser along with TED into the target hair follicles can explain the synergistic effect of fractional laser with topical triamcinolone used in this

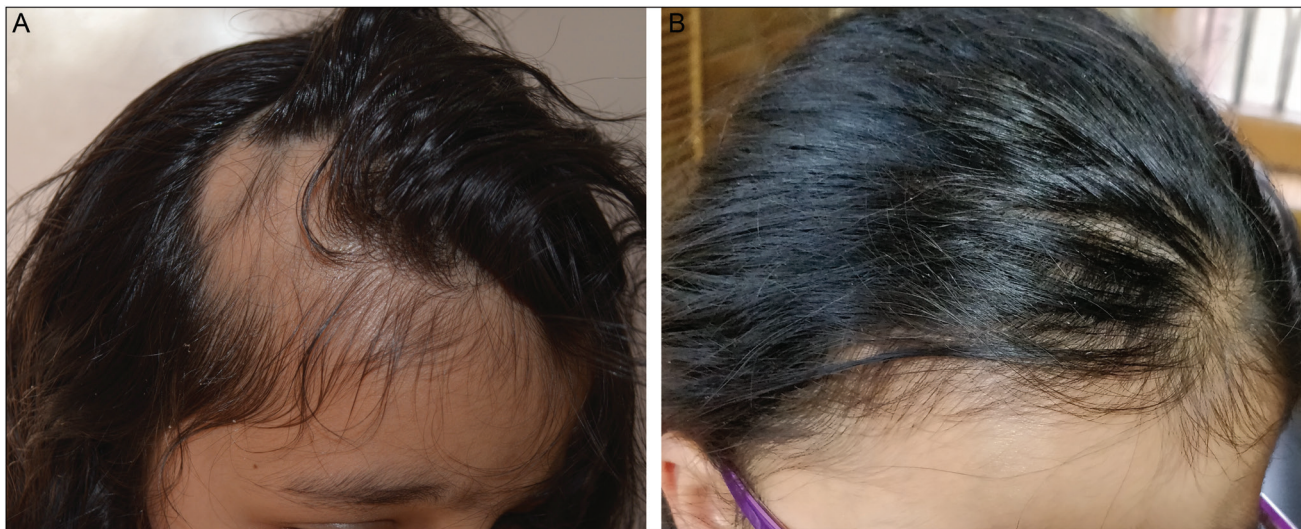

Figure 3: (A) Resistant alopecia areata in an 11-year-old female (Patient number 7). (B) Excellent response after treatment with fractional laser and steroid combination

case series. Both these mechanisms may be responsible for promoting hair regrowth in alopecia areata.^[11]

The technique of TED by fractional lasers has been applied for a range of clinical indications including precancerous lesions and nonmelanoma skin cancers,^[13] scars and keloids,^[6] dermatological diseases,^[7] and aesthetic conditions.^[14]

With this new technique using fractional CO₂ laser as TED system for triamcinolone, the drug can be delivered more homogeneously in the target area compared to that of needle injection, facilitating the therapeutic response. Moreover, the pain associated with repeated injections can be avoided if fractional laser is used instead of multiple pricks by intradermal injections. An additional possible advantage of using fractional lasers can be the reduced incidence of skin atrophy with topical triamcinolone.

In this case series, we could find a really significant therapeutic response in approximately 90% of cases treated with a combination of CO₂ fractional laser and topical triamcinolone. As seen in Table 1, all these patients had already been treated with multiple modalities and had not shown any positive therapeutic response to any of them. This is an additional pointer toward the therapeutic efficacy of this combination treatment in alopecia areata.

To the best of our knowledge, this is the first study documenting the therapeutic effect of fractional CO₂ laser with topical triamcinolone in alopecia areata.

CONCLUSION

Fractional CO₂ laser in combination with topical corticosteroid application shows excellent clinical response in resistant alopecia areata with negligible side effects. Besides, this novel method of TED reduces the pain and skin atrophy observed with intradermal injections of triamcinolone.

LIMITATION

This is a case series conducted in a limited number of patients, and we need larger studies carried out in more number of patients to confirm these results.

Declaration of patient consent

The authors certify that they have obtained all appropriate patient consent forms. In the form the patient(s) has/have given his/her/their consent for his/her/their images and other clinical information to be reported in the journal. The patients understand that their names and initials will not be published and due efforts will be made to conceal their identity, but anonymity cannot be guaranteed.

Financial support and sponsorship

Nil.

Conflicts of interest

There are no conflicts of interest.

REFERENCES

1. Messenger AG, McKillop J, Farrant P, McDonagh AJ, Sladden M. British Association of Dermatologists' guidelines for the management of alopecia areata 2012. *Br J Dermatol* 2012;166:916-26.
2. Hordinsky M, Donati A. Alopecia areata: an evidence-based treatment update. *Am J Clin Dermatol* 2014;15:231-46.
3. Bolduc CH, Shapiro J. The treatment of alopecia areata. *Dermatol Ther* 2001;14:306-16.
4. Perper M, Aldahan AS, Fayne RA, Emerson CP, Nouri K. Efficacy of fractional lasers in treating alopecia: a literature review. *Lasers Med Sci* 2017;32:1919-25.
5. Yoo KH, Kim MN, Kim BJ, Kim CW. Treatment of alopecia areata with fractional photothermolysis laser. *Int J Dermatol* 2010;49:845-7.
6. Waibel JS, Wulkan AJ, Shumaker PR. Treatment of hypertrophic scars using laser and laser assisted corticosteroid delivery. *Lasers Surg Med* 2013;45:135-40.
7. Majid I. Fractional carbon dioxide laser in combination with topical corticosteroid: an innovative treatment for hypertrophic lichen planus. *J Am Acad Dermatol* 2017;77:e67-8.

8. Jacques SL, McAuliffe DJ, Blank IH, Parrish JA. Controlled removal of human stratum corneum by pulsed laser. *J Invest Dermatol* 1987;88:88-93.
9. Manstein D, Herron GS, Sink RK, Tanner H, Anderson RR. Fractional photothermolysis: a new concept for cutaneous remodeling using microscopic patterns of thermal injury. *Lasers Surg Med* 2004;34:426-38.
10. Cho S, Choi MJ, Zheng Z, Goo B, Kim DY, Cho SB. Clinical effects of non-ablative and ablative fractional lasers on various hair disorders: a case series of 17 patients. *J Cosmet Laser Ther* 2013;15:74-9.
11. Lee GY, Lee SJ, Kim WS. The effect of a 1550nm fractional erbium-glass laser in female pattern hair loss. *J Eur Acad Dermatol Venereol* 2011;25:1450-4.
12. Bae JM, Jung HM, Goo B, Park YM. Hair regrowth through wound healing process after ablative fractional laser treatment in a murine model. *Lasers Surg Med* 2015;47:433-40.
13. Togsverd-Bo K, Haak CS, Thaysen-Petersen D, Wulf HC, Anderson RR, Hædersdal M, *et al.* Intensified photodynamic therapy of actinic keratoses with fractional CO₂ laser: a randomized clinical trial. *Br J Dermatol* 2012;166:1262-9.
14. Mahmoud BH, Burnett C, Ozog D. Prospective randomized controlled study to determine the effect of topical application of botulinum toxin A for crow's feet after treatment with ablative fractional CO₂ laser. *Dermatol Surg* 2015;41: S75-81.