


Case Report

Accidental intradermal injection of formalin – A case report

Amit Shivaji Kerure¹ , Sonia Sabhandasani¹, Khilchand Dilip Bhangale², Harshal Rewatkar³

¹Department of Dermatology, Dr. Amit Kerure Skin Clinic, ²Department of General Surgery, D. Y. Patil School of Medicine, Navi Mumbai, ³Department of Dermatology, Sparsh Skin Clinic, Nagpur, Maharashtra, India.

***Corresponding author:**

Sonia Sabhandasani,
Department of Dermatology,
Dr. Amit Kerure Skin Clinic,
Navi Mumbai, Maharashtra,
India.

soniasabhandasani.92@gmail.com

Received: 31 August 2023
Accepted: 01 November 2023
Epub Ahead of Print: 06 September 2024
Published:

DOI
[10.25259/jcas_148_23](https://doi.org/10.25259/jcas_148_23)

Quick Response Code:



ABSTRACT

Formalin solution can be called a “double-edged sword.” Known for its preservative and disinfectant properties, this aqueous chemical is widely used in the medical field. In dermatology, it is useful in preserving the skin tissue specimen for histopathology. However, if not handled with care, it can potentially cause severe dermatitis, first- or second-degree burns, ulcers in some cases, and even cellulitis. We, here, present a rare unfortunate case of an accidental injection of formalin, instead of a local anesthetic, as a test dose, on the forearm of a 28-year-old man at our clinic and its successful management.

Keywords: Formalin, Local anesthetic, Hypersensitivity

INTRODUCTION

Formalin is a 35 – 40% aqueous solution of formaldehyde.¹ It is a colorless, volatile liquid having a pungent odor.² Due to its disinfectant, antiseptic, and fixative properties, this chemical is widely used in the medical field. However, this solution needs to be handled with utmost care as it can potentially cause first-degree and second-degree burns on exposure to skin or mucosa. The Occupational Safety and Health Administration recognizes that contact with formaldehyde can cause skin irritation and dermatitis.³ Similarly, it has a deleterious effect on the gastrointestinal and respiratory system if ingested or inhaled.¹ Accidental injection of formalin intradermally represents a case of medical negligence and also leads to a unique opportunity to learn and analyze the corrosive effects of this chemical and the level of destruction, it may cause to both, the patient and the doctor.

CASE REPORT

A 28-year-old male patient reported to our skin clinic with the chief complaints of asymptomatic swelling on the back for 3 months. He had noticed the swelling to be increasing in size. Clinical examination revealed a cyst, approximately 3 × 4 cm in size, with a tiny punctum on its surface. Clinically, the lesion was diagnosed as a sebaceous cyst. Although asymptomatic, the size of the cyst caused discomfort to the patient while sleeping or resting his back against a chair. Hence, surgical removal of the same was planned. The surgery was to be performed by a visiting surgeon in the clinic. After taking written informed consent, and adequate and appropriate pre-surgical aseptic measures, the surgeon in charge loaded an insulin syringe with 4 units of lignocaine, to

This is an open-access article distributed under the terms of the Creative Commons Attribution-Non Commercial-Share Alike 4.0 License, which allows others to remix, transform, and build upon the work non-commercially, as long as the author is credited and the new creations are licensed under the identical terms.

©2024 Published by Scientific Scholar on behalf of Journal of Cutaneous and Aesthetic Surgery

inject intradermally as a test dose. Within a minute after injecting, the patient complained of sharp burning pain and intense discomfort at the site of injection. The procedure was stopped immediately. A quick clinical examination showed a deep erythema around the injection site [Figure 1]. The surgeon in charge immediately asked his assistant to examine the contents of the vial from which the syringe was loaded. A quick scan revealed that the vial contained a clear liquid having an offensive pungent odor. The assistant also informed a common practice in the clinic of using empty lignocaine bottles to preserve skin biopsy samples for histopathology and that it could contain formalin as a fixative. Soon after, the surgeon tried to aspirate the contents out to limit the tissue damage. The cyst removal was rescheduled for a later date. While discharging, the patient was prescribed prophylactic broad-spectrum antibiotics along with analgesics for 7 days and he was asked to follow up in the clinic regularly to keep a check on the injection site. The next day, the patient presented with a blister at the injection site, surrounded by a bluish necrotic tissue and an erythematous rim at the border [Figure 2]. Tenderness, pain, and burning sensation remained persistent. On the 4th day, the patient developed an ulcer at the injection site. The wound was cleaned meticulously and followed by a dressing. Thereafter, the patient was asked to follow up in the clinic daily for a change of dressing and for us to monitor the course of the ulcer. The patient had an uneventful recovery and after almost 6 weeks, the ulcer eventually healed with a hypertrophic scar [Figure 3].

DISCUSSION

There are not many incidents like this reported in the literature before and this case might even be one of its kind, as far as dermatosurgery is concerned. When an individual sustains an injury as a direct consequence of cosmetic treatment that he/she has received, it constitutes an act of medical negligence. Therefore, a thorough knowledge of

the medicines is mandatory for both, the surgeon as well as the assistant.⁴ In dermatology, there are many colorless chemicals like normal saline, formalin, local anesthesia, hydrogen peroxide etc used simultaneously for different purposes.¹ Proper storage or labeling of these solutions would help avoid confusion and mishaps. Secondly, the practice of reusing empty local anesthetic vials for storage of biopsy specimens instead of separately labeled biopsy bottles is another reason for such accidents.³ To avoid this, it is advisable to keep the non-injectable solutions away from the core clinical area. A similar case was reported by Bector A et al wherein formalin was accidentally injected in the oral cavity while performing a dental extraction, which resulted in chemical facial cellulitis.⁵ Lastly, like they say, mistakes

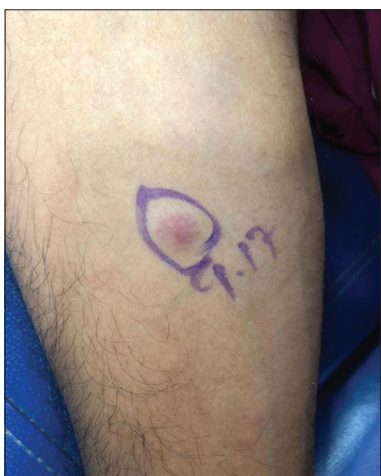

Figure 1: Soon after injecting formalin.

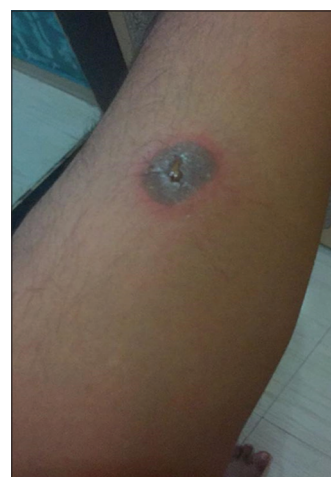

Figure 2: Day 2. The patient presented with a blister surrounded by bluish discoloration and an erythematous border.

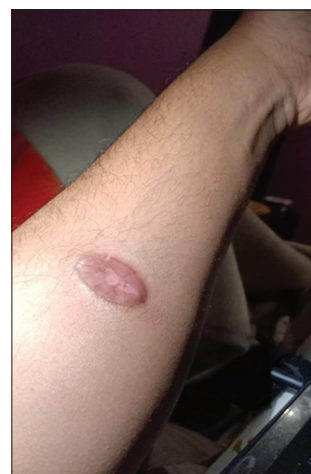

Figure 3: Wound healed with a hypertrophic scar by the end of 6 weeks.

are stepping stones towards success. In such problematic situations, it is important to not panic at that moment and rather handle the situation with utmost care.⁴ This case can be seen as an opportunity to learn the effects of such corrosive chemicals, its proper management and precautions to avoid such accidents in future.

CONCLUSION

The incident described underscores the critical importance of meticulous attention to detail and adherence to safety protocols in dermatosurgery and medical procedures involving potentially harmful substances. While such occurrences may be rare, they highlight the severe consequences that can arise from even minor lapses in procedure or storage of medical solutions. It is imperative for medical professionals, including surgeons and their assistants, to possess comprehensive knowledge of the medications and chemicals they use, ensuring proper labeling, storage, and handling at all times.

Authors' contribution

Amit S. Kerure, Dilip K. Bangle, Harshal Rewatkar and Sonia Sabhandasani: Conceived and designed the analysis, Collected the data, Contributed data or analysis tools, Performed the analysis, Wrote the paper.

Ethical approval

Institutional Review Board Approval is not required.

Declaration of patient consent

The authors certify that they have obtained all appropriate patient consent.

Financial support and sponsorship

Nil.

Conflicts of interest

There are no conflicts of interest.

Use of artificial intelligence (AI)-assisted technology for manuscript preparation

The authors confirm that there was no use of artificial intelligence (AI)-assisted technology for assisting in the writing or editing of the manuscript and no images were manipulated using AI.

REFERENCES

1. Singha S, Daryani H, Aggarwal K, Agrawal A, Pathi J. Accidental intraoral formalin injection as local anesthetic agent in an outreach activity: A rare case report. *Biomed J Sci Tech Res* 2018;10:7842-4.
2. Chandra P, Prasad R. Unintended formalin injection instead of local anesthetic agent: Its causes and management. *Int J Contemp Med Res* 2020;7:C1-2.
3. Dandriyal R, Giri KY, Alam S, Singh AP. Accidental intraoral formalin injection: A rare case report. *Clin Pract* 2014;4:686.
4. Singh C, Aggarwal M. Accidental injection of formalin in dental operatory: case report. *International Journal of Contemporary Medical Research* 2016;3:727-8.
5. Bector A, Virk PS, Arakeri G. Chemical facial cellulitis due to inadvertent injection of formalin into oral tissue space. *Clin Pract* 2015;5:810.

How to cite this article: Kerure AS, Sabhandasani S, Bhangale KD, Rewatkar H. Accidental intradermal injection of formalin – A case report. *J Cutan Aesthet Surg*. doi: 10.25259/jcas_148_23