

# Platelet-Rich Plasma in Androgenic Alopecia: Myth or an Effective Tool

Swapna S Khatu, Yuvraj E More, Neeta R Gokhale, Dipali C Chavhan, Nitin Bendsure

Department of Dermatology, Venereology and Leprosy, Smt Kashibai Navale Medical College, Pune, Maharashtra, India

**Address for correspondence:** Dr. Swapna S. Khatu, Department of Dermatology, Venereology and Leprosy, Smt Kashibai Navale Medical College, Narhe, Pune - 411 041, Maharashtra, India. E-mail: drswapnakhatu@gmail.com

## ABSTRACT

Platelet-rich plasma (PRP) has become a newer method for the treatment of various types of alopecia. In this prospective study, safety, efficacy and feasibility of PRP injections in treating androgenic alopecia were assessed. Eleven patients suffering from hair loss due to androgenic alopecia and not responding to 6 months treatment with minoxidil and finasteride were included in this study. The hair pull test was performed before every treatment session. A total volume of 2-3 cc PRP was injected in the scalp by using an insulin syringe. The treatment was repeated every two weeks, for a total of four times. The outcome was assessed after 3 months by clinical examination, macroscopic photos, hair pull test and patient's overall satisfaction. **Results:** A significant reduction in hair loss was observed between first and fourth injection. Hair count increased from average number of 71 hair follicular units to 93 hair follicular units. Therefore, average mean gain is 22.09 follicular units per cm<sup>2</sup>. After the fourth session, the pull test was negative in 9 patients. **Conclusion:** PRP injection is a simple, cost effective and feasible treatment option for androgenic alopecia, with high overall patient satisfaction.

**KEYWORDS:** Androgenic alopecia, platelet rich plasma, hair pull test

### REC Review:

Risk : 5	0 = maximum risk	5 = least risk
Efficacy : 2	0 = minimum efficacy	5 = maximum efficacy
Cost : 2	0 = very expensive	5 = least expensive

## INTRODUCTION

Androgenic alopecia or male pattern baldness is a very common type of hair loss observed in both males and females. Platelet-rich plasma (PRP) is an autologous preparation of platelets in concentrated plasma. Although the optimal PRP platelet concentration is unclear, the current methods by which PRP is prepared report 300-700% enrichment, with platelet concentrations consequently increasing to more than 1,000,000 platelets/L.<sup>[1]</sup> PRP has attracted attention in several medical fields because of its ability to promote wound healing. Activation of alpha granules of platelets releases numerous proteins, including platelet-derived

growth factor (PDGF), transforming growth factor (TGF), vascular endothelial growth factor (VEGF), insulin-like growth factor (IGF), epidermal growth factor (EGF) and interleukin (IL)-1.<sup>[2,3]</sup> It is hypothesised that growth factors released from platelets may act on stem cells in the bulge area of the follicles, stimulating the development of new follicles and promoting neovascularisation.<sup>[4]</sup> The aim our pilot study was to evaluate the safety, efficacy and feasibility of PRP for treatment of androgenic alopecia.

## MATERIALS AND METHODS

Between August 2013 and November 2013, all patients suffering from androgenic alopecia and on topical minoxidil and finasteride for at least 6 months without much improvement were considered for PRP therapy. Written informed consent was obtained. All included patients were tested by ELISA for HIV, HBS Ag and platelet count. Exclusion criteria were haematological disorders, thyroid dysfunction, malnutrition and other dermatological disorders contributing to hair loss. A 1 cm × 1 cm square area was marked over right parietal area in mid-pupillary line, 10 cm proximal to right eyebrow in each patient. Baseline follicular units were manually counted with the help of trichoscan in this area by dividing into four small quadrants [Figures 1 and 2].

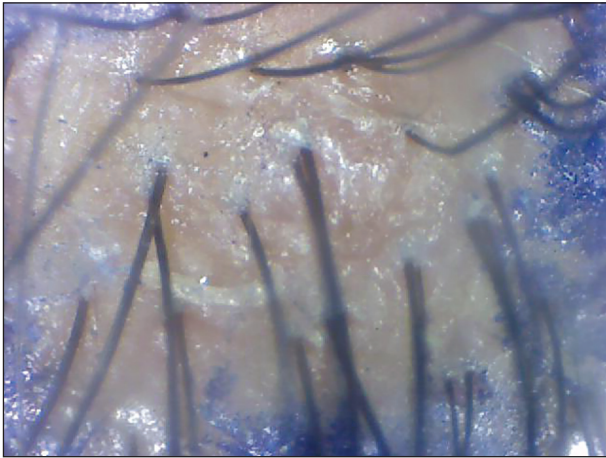
### Access this article online

#### Quick Response Code:



**Website:**  
www.jcasonline.com

**DOI:**  
10.4103/0974-2077.138352

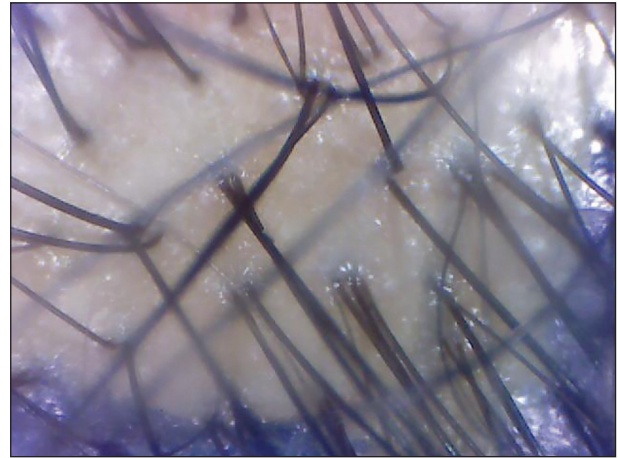


**Figure 1: Pre-treatment trichoscan image**

Before each session, the hair pull test was performed three times by the same clinician. All patients were advised to avoid washing hair two days prior to the treatment. A bundle of approximately 50-60 hair was grasped between the thumb, index and middle finger from the base close to the scalp. The hair was firmly tugged away from the scalp, and the extracted hair was counted in every session. To evaluate overall hair growth, hair volume, hair quality and fullness, global pictures were taken in every session from front, vertex, lateral and back view.

PRP was prepared by collecting 20 cc of fresh blood in sodium citrate containing vaccutainers in minor operation theatre under proper aseptic precaution. The tubes were rotated in a centrifugation machine at 1500 revolutions per minute for 6 minutes. The first centrifugation is called "soft spin", which allows blood separation into three layers, namely bottom RBC layer (55% of total volume), topmost acellular plasma layer called platelet poor plasma (PPP, 40% of total volume) and an intermediate PRP layer (5% of total volume) called the "buffy coat". Separated buffy coat with PPP was collected with the help of Finn pipette in another test tube. This tube underwent a second centrifugation, which was longer and faster than the first, called "hard spin", comprising at 2500 revolution per minute for 15 minutes. This allows the platelets (PRP) to settle at the bottom of the tube. The upper layer containing PPP was discarded and the lower layer of PRP was loaded in an insulin syringe containing calcium chloride (1 part calcium chloride and 9 parts of PRP) as an activator.<sup>[5]</sup>

One hour prior to administration of PRP, anaesthetic cream was applied over the bald area. Area of the scalp to be treated was cleaned with cetavlon, spirit and povidone-iodine. With the help of insulin syringe PRP was injected over affected area by nappage technique (multiple small injections in a linear pattern one-



**Figure 2: Post-treatment trichoscan image**

cm apart) under proper aseptic precaution in minor operation theatre. A total volume of 2-3 cc was injected. The treatment was repeated every two weeks for four sessions. At each visit, hair count was noted over the prefixed square area. Subjective improvements of patients were noted on a scale of worst (1) to best (10). We evaluated all the patients at the end of 12 weeks.

## RESULTS

Eleven male patients in the age group of 20-40 years were included in the study. According to Hamilton classification of male pattern baldness, 4 patients were in grade 2, 4 patients were in grade 3 and 3 patients were in grade 4 androgenic alopecia.

Before treatment, all our patients (100%) had a positive hair pull test with mean number of 10 hair. After the fourth session, the pull test was negative in 9 patients (81.81%) with average number of three hairs. A significant reduction in hair loss was observed between first and fourth injection as noticed by patients. Global pictures also revealed a moderate improvement in hair volume and coverage. [Figures 3 and 4] Hair count depicted average number of 71 hair follicular units over marked area before starting the treatment, and after 4 sessions of PRP, average number of follicular units was 93.09 follicular units. Therefore, average mean gain is 22.09 follicular units per cm<sup>2</sup>. Overall, patient satisfaction was high with a mean result rating of 7.0 on a scale of 1-10.

The side effects after PRP injections were minimal pain, redness at the time of injections and pinpoint bleeding.

## DISCUSSION

Hair loss has a significant influence on psychological distress and is associated with low self-esteem and depression. Treatment options for androgenic alopecia are very limited and include topical minoxidil and

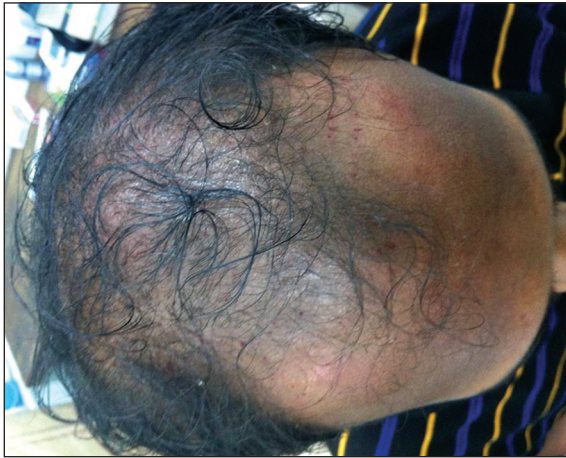

Figure 3: Pre-treatment clinical photograph

oral finasteride (FDA approved) either alone or in combination.<sup>[6,7]</sup> However, there are several reported side effects such as headache and increase in other body hairs for minoxidil<sup>[6]</sup> whereas loss of libido has been reported with oral finasteride. Finasteride also interferes with genital development in a male fetus and is contraindicated in pregnant women and those likely to become pregnant.<sup>[7,8]</sup>

PRP has already attracted attention in plastic surgery, orthopaedic surgery and cardiac surgery because of its potential use in skin rejuvenating effects, rapid healing, reduced infection, decreased chance of hypertrophic keloids and scars.<sup>[9,10]</sup> Growth factors are known to activate the proliferative phase and transdifferentiation of hair and stem cells and produce new follicular units. bFGF is reported to promote the in vitro proliferation of papilla cells, and thereby plays a key role in elongating hair shaft.<sup>[11]</sup>

We prepared PRP by double spin method, in which blood cell layers were manually separated. Activation of platelets through coagulation triggers the secretion of various growth factors, which produce mitogenic effects in various cell types. Activated PRP promotes the proliferation of dermal papillary cells and prevents their apoptosis.

In our study, the hair pull test became negative after four sessions of PRP. This finding is comparable with the study conducted by Besti *et al.*<sup>[12]</sup> This study also observed significant improvement in hair volume and coverage in global pictures, but according to our study, only moderate improvement in hair volume and coverage was observed.<sup>[12]</sup>

Uebel *et al.* observed a significant improvement in hair density and stimulation of growth when follicular units were pre-treated with platelet plasma growth factors before their implantation. There was a significant

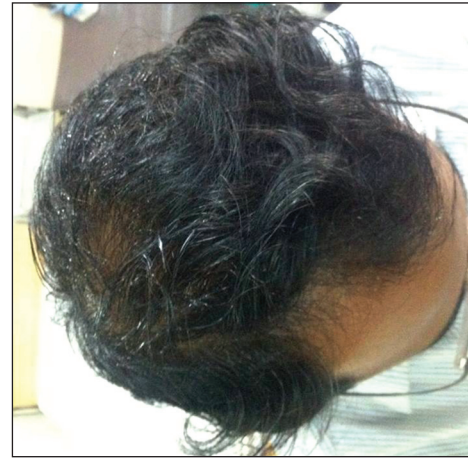

Figure 4: Post-treatment clinical photograph

difference in the yield of follicular units on comparing the experimental with the control areas of the scalp. The areas treated with platelet plasma growth factors demonstrated a yield of 18.7 follicular units per cm<sup>2</sup> whereas the control areas yielded 16.4 follicular units per cm<sup>2</sup>, an increase in follicular density of 15.1 percent.<sup>[4]</sup>

Our study has some limitations. Trichoscopic hair evaluation could have given more objective results. Sample size is very small. Mean follow up of patients is also short to draw conclusion regarding the long-term effectiveness of treatment. Thus, further studies are needed with longer follow up and with large sample size.

## CONCLUSION

PRP injection for androgenic alopecia is a simple, cost-effective and feasible treatment option for hair loss and can be regarded as a valuable adjuvant treatment modality for androgenic alopecia. Although PRP has sufficient theoretical scientific basis to support its use in hair restoration, hair restoration using PRP is still at its infancy. Clinical evidence is still weak. Considering its excellent safety profile and relatively low cost, PRP hair treatment is a promising treatment option for patients with thinning hair.

## ACKNOWLEDGEMENT

We would like to acknowledge Dr Vimal Arun Harke for helping us in preparing PRP.

## REFERENCES

1. Li ZJ, Choi HM, Choi DK, Sohn KC, Im M, Seo YJ, *et al.* Autologous platelet rich plasma: A potential therapeutic tool for promoting hair growth. *Dermatol Surg* 2012;38:1040-6.
2. Marx RE. Platelet-rich plasma: Evidence to support its use. *J Oral Maxillofac Surg* 2004;62:489-96.
3. Eppley BL, Pietzak WS, Blanton M. Platelet-rich plasma: A review of biology and applications in plastic surgery. *Plast Reconstr Surg* 2006;118:147-59e.

4. Uebel CO, da Silva JB, Cantarelli D, Martins P. The role of platelet plasma growth factors in male pattern baldness surgery. *Plast Reconstr Surg* 2006;118:1458-66.
5. Sunitha Raja V, Munirathnam Naidu E. Platelet-rich fibrin: Evolution of a second-generation platelet concentrate. *Indian J Dent Res* 2008;19:42-6.
6. Olsen EA, Weiner MS, DeLong ER, Pinnell SR. Topical minoxidil in male pattern baldness. *J Am Acad Dermatol* 1985;13:185-92.
7. Kaufman KD, Olsen EA, Whiting D, Savin R, DeVillez R, Bergfeld W, *et al.* Finasteride in the treatment of androgenic alopecia. *J Am Acad of Dermatol* 1998;39:578-89.
8. Messenger AG. Medical management of male pattern hair loss. *Int J Dermatol* 2000;39:585-6.
9. Gardner MJ, Demetrakopolous D, Klepchick PR, Mooar PA. The efficacy of autologous platelet gel in pain control and blood loss in total knee arthroplasty. An analysis of the haemoglobin, narcotic requirement and range of motion. *Int Orthop* 2007;31:309-13.
10. Glover JL, Weingarten MS, Buchbinder DS, Poucher RL, Deitrick GA 3rd, Fylling CP. A 4-year outcome based retrospective study of wound healing and limb salvage in patients with chronic wounds. *Adv Wound Care* 1997;10:33-8.
11. Katsuoka K, Schell H, Wessel B, Hornstein OP. Effects of epidermal growth factor, fibroblast growth factor, minoxidil and hydrocortisone on growth kinetics in human hair bulb papilla cells and root sheath fibroblasts cultured *in vitro*. *Arch Dermatol Res* 1987;279:247-50.
12. Besti EE, Germain E, Kalbermatten DF, Tremp M, Emmenegger V. Platelet-rich plasma injection is effective and safe for the treatment of alopecia. *Eur J Plast Surg* 2013;36:407-12.

**How to cite this article:** Khatu SS, More YE, Gokhale NR, Chavhan DC, Bendsure N. Platelet-rich plasma in androgenic alopecia: Myth or an effective tool. *J Cutan Aesthet Surg* 2014;7:107-10.

**Source of Support:** Nil. **Conflict of Interest:** None declared.