

Clinicopathological Profile of Nodular Hidradenoma: A ten year Study in a Tertiary Care Center

M. Arthi, Leena D. Joseph, K. Arun Kumar¹

Department of Pathology, ¹Sri Ramachandra Institute of Higher Education and Research, Chennai, Tamil Nadu, India

Abstract

Nodular hidradenoma is a rare skin adnexal tumor of eccrine differentiation with predominant site being scalp and axillae. Due to its variable locations and unusual clinical presentation and no definite radiological criteria, histopathology seems to be the mainstay in diagnosing these tumors. Most of the lesions present as a cystic swelling and was clinically thought to be a sebaceous cyst/metastasis/carcinoma/sarcoma. In our study, we have included 37 cases and compared its varied clinical and radiological presentation.

Keywords: Histopathology, nodular hidradenoma, skin adnexal tumor

INTRODUCTION

Nodular hidradenoma is a benign adnexal tumor that arises from the distal excretory duct of eccrine sweat gland. Nodular hidradenoma resembles the cells and structures of ductal segment of the eccrine sweat gland, hence the name.^[1] Most of the cases previously reported as eccrine now have been reclassified as apocrine. The usual presentation of this tumor is slowly enlarging, solitary, freely movable nodule, solid or cystic, measuring on an average 0.5–2cm in diameter, but may reach 6.0cm or more.^[2] The common locations of the lesion are axilla, face, arms, thighs, trunk, scalp, and pubic region but the most common site is head. Most commonly it is seen in the age group of 20–50 years and is rare in children.^[2] It occurs in women twice as commonly as in men.^[2]

Histologically, the tumor is composed of lobulated masses located in the dermis and extending into the subcutaneous fat.^[3] Epidermal connection is present in up to one-third of the cases. It is composed of two cell types: the polygonal cells, whose glycogen content may give the cytoplasm a clear appearance, and elongated, darker, and smaller cells, which may appear at the periphery. The tumor may be solid or cystic in varying proportions.

Malignant transformation is very rare and if does, takes years to transform in to a malignant neoplasm.^[4]

Due to its varied location and cystic nature of the lesion, it poses a clinical and radiological diagnostic challenge.^[5]

Objective

The objective is to study the clinical and pathological spectrum of nodular hidradenoma in a tertiary care center.

MATERIALS AND METHODS

This is an observational study done at a tertiary care hospital in South India. All skin adnexal tumor with the histological diagnosis of nodular hidradenoma presented to the Department of pathology from 2011 to 2021 were included in the study. This is a 10-year study, where we got 37 cases. Clinical details of the patient such as age, sex, site, and size were noted. Provisional diagnosis of the lesion was obtained from the histopathological requests. Radiological investigation if done was noted. The lesions were grouped and the results were compared. The clinical and radiological diagnosis was compared with the final histological diagnosis.

Address for correspondence: Dr. K. Arun Kumar,

Department of Pathology, Sri Ramachandra Institute of Higher Education and Research, Chennai 600116, Tamil Nadu, India.
E-mail: arunkumar.k@sriramachandra.edu.in

Access this article online

Quick Response Code:



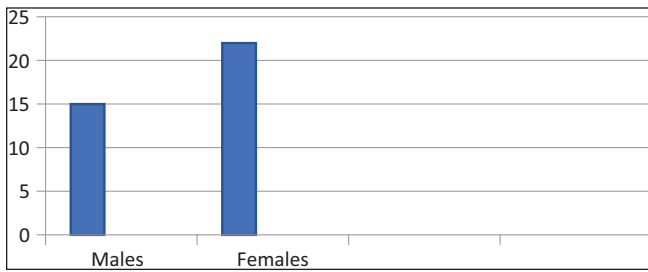
Website:
www.jcasonline.com

DOI:
10.4103/JCAS.JCAS_125_21

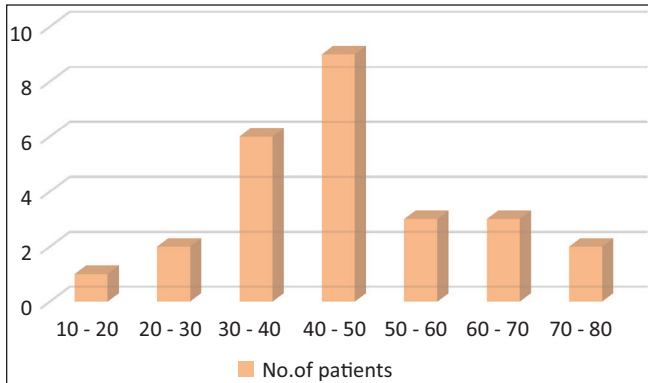
This is an open access journal, and articles are distributed under the terms of the Creative Commons Attribution-NonCommercial-ShareAlike 4.0 License, which allows others to remix, tweak, and build upon the work non-commercially, as long as appropriate credit is given and the new creations are licensed under the identical terms.

For reprints contact: reprints@medknow.com

How to cite this article: Arthi M, Joseph LD, Arun Kumar K. Clinicopathological profile of nodular hidradenoma: A ten year study in a tertiary care center. *J Cutan Aesthet Surg* 2023;16:34-7.



Graph 1: Male/female distribution



Graph 2: Age distribution

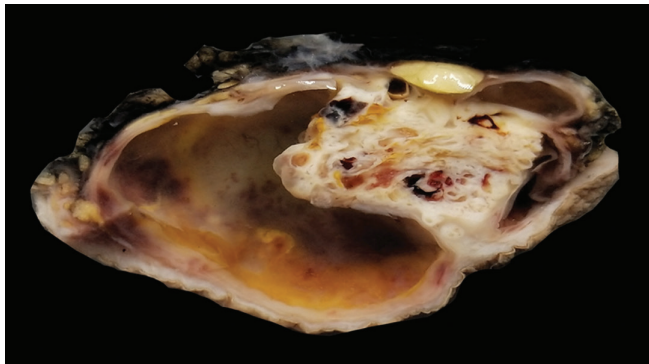


Figure 1: Gross of nodular hidradenoma showing solid and cystic swelling

Table 1: Clinical/radiological diagnosis of cases	
Clinical diagnosis	No. of cases
Sebaceous cyst/dermoid	48.6% (18)
Neurofibroma	5.4% (2)
Lymphatic cyst	8.1% (3)
Sarcoma	2.7% (1)
Metastasis	2.7% (1)
Cystic swelling	13.5% (5)
Without clinical diagnosis	13.5% (5)

Table 2: Malignant diagnosis clinically and radiologically			
Cases	Clinical diagnosis	Radiology	Pathological diagnosis
1.	Metastatic deposit (K/C/O Ca lung)	FDG avid lesion – possibly metastasis [Figure 2]	Nodular hidradenoma
2.	Dermoid cyst – scalp	Dermoid/dermatofibrosarcoma protruberans [Figure 3]	Clear cell hidradenoma
3.	Soft tissue sarcoma – forearm	Soft tissue sarcoma/ganglion cyst [Figure 4]	Nodular hidradenoma

RESULTS

A total of 37 cases were studied of which 15 were males and 22 females [Graph 1]. The age distribution ranges from 17-15 years [Graph 2].

On gross examination, most of the cases presented as solitary, well-circumscribed, solid, and cystic swelling with the size of the lesion ranging from 3.5 to 7.5 cm [Figure 1]. Clinical diagnosis of dermoid cyst was thought in approximately 50% of the cases. The other diagnoses were lymphatic cyst, metastasis, and sarcoma [Table 1]. Most of the tumors were from the scalp and axillae, and other sites included gluteal region, breast, chest, and vulva.

Among the 37 cases, three cases were radiologically diagnosed to be a malignant tumor [Table 2], which after histopathological microscopic features were proven to be nodular hidradenoma.

One of the cases was diagnosed to be a malignant deposit of scalp in a male patient with a history of known case of lung carcinoma, and in other two patients as sarcoma of one presented in forearm and other a midline mediastinal swelling.

Microscopy of the tumor were solitary, circumscribed [Figure 5], solid and cystic, dermal, symmetrical, lobulated tumors with a sheet-like and papillary architecture [Figure 6]. The solid area was composed of two types of cells: eosinophilic/polygonal cells and clear cells.

The shape of the eosinophilic cells vary from round to polygonal. They showed a rounded to ovoid nucleus, small distinct nucleoli, and faintly eosinophilic cytoplasm surrounded by hyalinized fibrovascular cores.

Clear cells showed abundant clear cytoplasm with a small, round to oval, eccentric nucleus. Some duct-like tubular structures were observed, which were constituted by cuboidal cells and filled with eosinophilic hyaline material. Cystic spaces were also filled with amorphous eosinophilic material. Occasional squamoid morules were also evident. No evidence of atypia, invasion, necrosis, and mitoses were noted in any of the cases.

DISCUSSION

Skin adnexal tumors often cause a diagnostic dilemma due to uncertain origin, varied clinical presentation, nonspecific radiological features, and overlapping morphology. But it is crucial to diagnose them as some of them have high incidence of recurrence and malignant

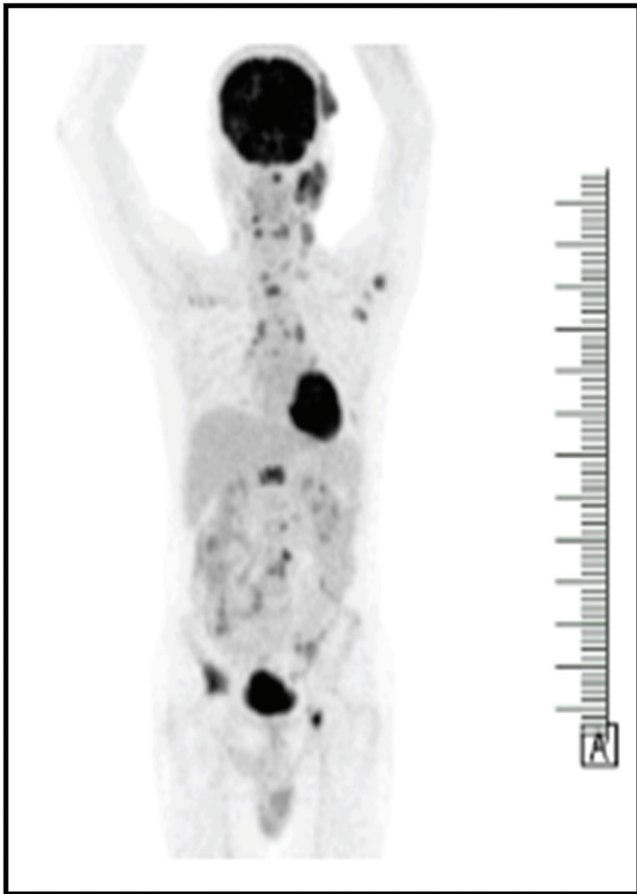


Figure 2: Case 1 FDG avid PET lesion in scalp

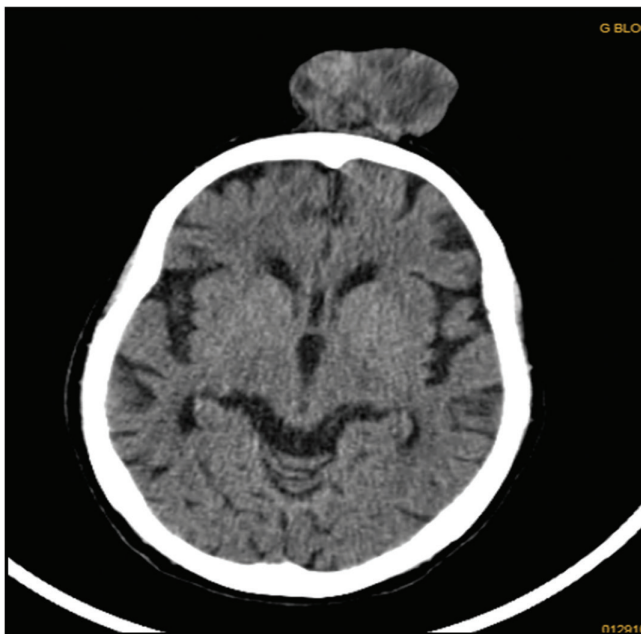


Figure 3: Case 2 CT scan of scalp lesion

potential. Nodular hidradenoma is one such skin adnexal tumor with varied clinical and morphological pattern, often misdiagnosed clinically and radiologically. It is a benign sweat gland neoplasm that is now reclassified

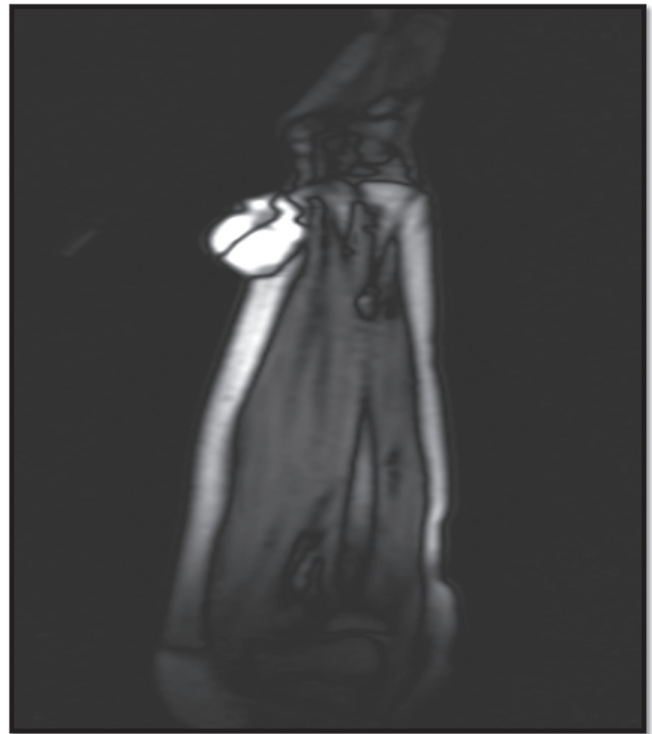

Figure 4: Case 3 MRI of soft tissue swelling of forearm

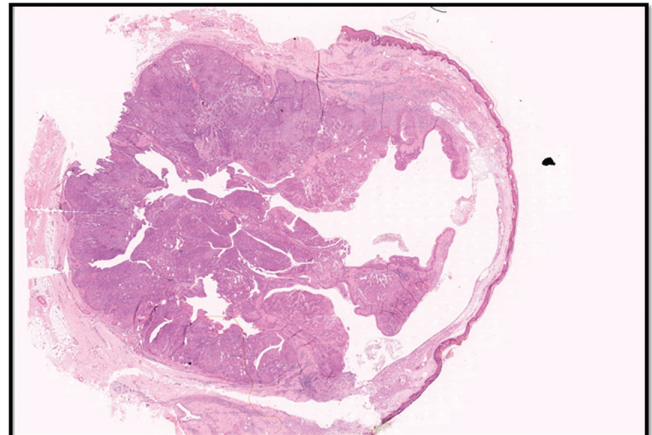


Figure 5: H&E scanner view showing well circumscribed solid and cystic lesion

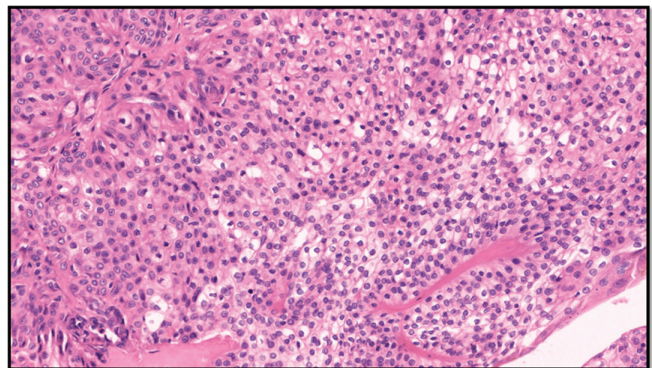


Figure 6: H&E 400× showing polygonal cells with eosinophilic and clear cytoplasm

as apocrine, occurs as a single mass in the skin with a nodular or cystic structure.^[5] It presents as a solitary, firm nodule with a slight predilection for the head, face, and upper extremities. Hernandez *et al.*^[6] in their study showed a female predominance (1.7:1), with a mean age at presentation of 37.2 years similar to our study, where females showed a predominance and the mean age being 40.1 years.

In our study, the most common site of involvement was scalp (35.5%) similar to that of Nandeesh *et al.*^[5] Grossly, the lesion is solid and cystic with serous fluid-filled cystic areas, mimicking a dermoid cyst.

Histologically, the lesion is well-circumscribed and sharply demarcated.^[6] The tumor is composed of solid and cystic spaces. Solid areas shows two types of cells, one being polyhedral cells with more basophilic cytoplasm and the other is round with a clear cytoplasm.^[7] The clear cells contain glycogen and periodic acid-Schiff-positive, diastase-resistant material, but no lipid.^[8] Clear cell hidradenoma, the most common variant, contains predominantly clear or pale cells with distinct cell borders.^[9] The intervening stroma varies from delicate vascularized cords of fibrous tissue to dense hyalinized collagen. Variable numbers of mitotic figures are noted, and the presence does not necessarily indicate malignancy.

Although immunohistochemistry can aid in confirmation of the diagnosis such as epithelial membrane antigen, carcinoembryonic antigen, and cytokeratin AE1/AE3, they are not often necessary.^[10]

Since the lesion is dermal origin, although epidermal connection is seen in up to one-third of the cases, they can grow to enormous sizes and radiologically mimic malignancy.^[11] Kyung *et al.* in his study elaborates on no specific radiological criteria to diagnose nodular hidradenoma, hence a radiological misdiagnosis is frequent.^[12] In our study, three cases were thought to be malignant radiologically, which eventually proved microscopically as nodular hidradenoma.

Malignant counterpart of hidradenoma is termed hidradenocarcinoma. Infiltrative growth pattern, deep extension, necrosis, nuclear pleomorphism, ≥ 4 mitoses per 10 high-power fields, and angiolymphatic invasion are specific features of hidradenocarcinomas.^[13] Souvatzidis *et al.* in their study says malignant transformation is rare and histologically characterized by nuclear atypia, necrosis, and abnormal mitoses.^[7] Malignant transformation is quite aggressive course with widely disseminated disease and death has been reported.^[13]

Wide surgical excision is the mode of treatment to minimize the risk of recurrence, with histological confirmation of the same.^[9] Inadequate excision of the tumor results in recurrence and is common, up to 10%.^[14] Adequate excision is recommended due to its high recurrence rate and potential

malignancy. Complete excision of the nodular hidradenoma with wide margins should prevent local recurrence.^[14]

CONCLUSION

Our study describes the clinical, pathological spectrum of the lesion. Although nodular hidradenoma is a benign lesion and excision is the only treatment, due to its varied clinical presentation, histopathology remains the main stay of diagnosis and helps to rule out the other skin appendageal tumors, certain benign and malignant conditions.

Acknowledgement

Nil.

Financial support and sponsorship

Nil.

Conflicts of interest

There are no conflicts of interest.

REFERENCES

1. Pushpa B, Duraisamy K. Study on morphological features of nodular hidradenoma. *Journal of Evolution of Medical and Dental Sciences* 2015;4:9140-5.
2. Winkelmann RK, Wolff K. Solid-cystic hidradenoma of the skin. *Clinical and histopathologic study. Arch Dermatol* 1968;97:651-61.
3. Kataria SP, Singh G, Batra A, Kumar S, Kumar V, Singh P. Nodular hidradenoma: A series of five cases in male subjects and review of literature. *Adv Cytol Pathol* 2018;3:46-7.
4. Hunt SJ, Santa Cruz DJ, Kerl H. Giant eccrine acrospiroma. *J Am Acad Dermatol* 1990;23:663-8.
5. Nandeesh BN, Rajalakshmi T. A study of histopathologic spectrum of nodular hidradenoma. *Am J Dermatopathol* 2012;34:461-70.
6. Gatti A, di Meo N, Trevisan G. Dermoscopy of eccrine acrospiroma masquerading as nodular malignant melanoma. *Acta Dermatovenerol Alp Pannonica Adriat* 2010;19:23-5.
7. Souvatzidis P, Sbrano P, Mandato F, Fimiani M, Castelli A. Malignant nodular hidradenoma of the skin: Report of seven cases. *J Eur Acad Dermatol Venereol* 2008;22:549-54.
8. Weedon D, Strutton G, Rubin AI, Weedon D. *Weedon's Skin Pathology*. Edinburgh: Churchill Livingstone/Elsevier; 2016;33. pp. 943-4.
9. Novak NP, Kaić G, Tomasić-Lončarić C, Zic R, Skoro M, Ostović KT. Fine-needle aspiration cytology of apocrine hidradenoma. *Coll Antropol* 2010;34:671-4.
10. Benkirane S, BayBay H, Bennani M, Oulehri A, Mernissi FZ. Nodular hidradenoma case of rare localization. *Asploro Journal of Biomedical and Clinical Case Reports* 2020;2020:18.
11. Biddlestone LR, McLaren KM, Tidman MJ. Malignant hidradenoma—a case report demonstrating insidious histological and clinical progression. *Clin Exp Dermatol* 1991;16:474-7.
12. Cho KE, Son EJ, Kim JA, Youk JH, Kim EK, Kwak JY, *et al.* Clear cell hidradenoma of the axilla: A case report with literature review. *Korean J Radiol* 2010;11:490-2.
13. Nazarian RM, Kapur P, Rakheja D, Piris A, Duncan LM, Mihm MC Jr, *et al.* Atypical and malignant hidradenomas: A histological and immunohistochemical study. *Mod Pathol* 2009;22:600-10.
14. Calonje E, Brenn T, Lazar A. *McKee's Pathology of the Skin with Clinical Correlations*. 4th ed. China: Elsevier Saunders; 2012. pp. 1571-4.