

# Papular Acne Scars of the Nose and Chin: An Under-recognised Variant of Acne Scarring

Faisal R Ali, Michael Kirk, Vishal Madan

Dermatology Centre, Salford Royal NHS Foundation Trust, Manchester, United Kingdom

**Address for correspondence:** Dr. Vishal Madan, Dermatology Centre, Salford Royal NHS Foundation Trust, Stott Lane, Manchester M6 8HD, United Kingdom. E-mail: vishal.madan@srfh.nhs.uk

## ABSTRACT

**Background:** Scarring following acne vulgaris is common and can be of profound psychosocial consequence. **Aims and Objectives:** We have clinically noted a variant of acne scarring, overlooked by previous categorisation schemes, which we have denominated as papular acne scars of the nose and chin. We sought to characterise these novel entities further. **Materials and Methods:** Initially, we identified 14 patients with papular acne scars of the nose and chin in a cosmetic dermatology clinic, of whom two were female and rest were male. We then prospectively evaluated 100 consecutive patients attending our tertiary referral acne isotretinoin clinic and 49 patients attending a general dermatology clinic. **Results:** Amongst 149 patients, from a general dermatology and tertiary acne clinic, soft papular scars were noted in four patients, distributed on the nose and chin. Three of the four patients were male, three patients had additional acne scars and the median age was 23.5. **Conclusions:** We have identified 18 patients with papular acne scars of the nose and chin and propose that this new category should be added to acne scarring classification schemes. Future work should be directed at corroborating the epidemiology of such lesions and describing effective treatment modalities.

**KEYWORDS:** Acne scars, acne vulgaris, categorisation, papular scars

## INTRODUCTION

Acne vulgaris is a chronic inflammatory disorder of the pilosebaceous unit that affects almost all individuals during adolescence, being moderate to severe in 15–20% of cases.<sup>[1,2]</sup> Underlying aetiological factors include increased sebum production, *Propionibacterium acnes* colonisation, follicular hyperkeratosis and inflammation.

Scarring is one of the most enduring sequelae of acne and it is associated with profound psychosocial morbidity.<sup>[3]</sup> In patients with active acne, up to 95% of individuals are reported to demonstrate some degree of facial scarring,<sup>[4]</sup> with delayed treatment and severity of acne associated with the extent and severity of scarring. Acne scarring has previously been categorised into increased tissue

formation (including hypertrophic and keloid scars) and loss of tissue (including the entities of ice pick, rolling and boxcar scars), with each subcategory of scar requiring nuanced therapeutic approaches.<sup>[5]</sup>

Amongst adolescents with acne vulgaris, we have empirically observed a subphenotype of scarring following acne vulgaris, comprising multiple non-scaling skin-coloured soft fibrous papules, all 2–4 mm in diameter, distributed typically over the nasal skin and the chin. We aimed to further characterise these soft papular acne scars of the nose and chin, which are phenotypically distinct from the previously described subtypes of acne scarring.

This is an open access article distributed under the terms of the Creative Commons Attribution-NonCommercial-ShareAlike 3.0 License, which allows others to remix, tweak, and build upon the work non-commercially, as long as the author is credited and the new creations are licensed under the identical terms.

**For reprints contact:** reprints@medknow.com

**How to cite this article:** Ali FR, Kirk M, Madan V. Papular acne scars of the nose and chin: An under-recognised variant of acne scarring. *J Cutan Aesthet Surg* 2016;9:241-3.

### Access this article online

#### Quick Response Code:



**Website:**  
www.jcasonline.com

**DOI:**  
10.4103/0974-2077.197075

## MATERIALS AND METHODS

Initially, a series of patients with papular acne scars of the nose and chin were identified in a cosmetic dermatology clinic.

To establish the prevalence and characteristics of these papular scars in the acne population, we prospectively evaluated 100 consecutive patients attending our tertiary referral acne isotretinoin clinic, in whom patients are all judged to have acne for which isotretinoin is indicated. Typically, patients are referred to this clinic in view of disease recalcitrant to topical therapy and systemic antibiotics or who have evidence of scarring.

We subsequently analysed a further 49 patients with acne attending general dermatology clinic to see whether the prevalence of soft papular scars of the nose and chin may be different in this group of patients.

## RESULTS

Initially, 14 cases of papular scarring were identified in a cosmetic dermatology clinic, to which patients attend for improvement of their acne scarring. Soft papular scars affected the nose in ten cases [Figure 1a and b], the chin in four cases [Figure 2a and b] and both sites in one case. Of the 14 patients, 2 were female. Histological examination of a representative lesion from one patient showed fibrous scarring together with a few ectatic blood vessels and mild chronic inflammation [Figure 3]. We estimated that these papules were being seen in 10–15% of the patients with acne scarring attending the cosmetic dermatology clinic.

Of the 100 consecutive patients attending the tertiary referral acne isotretinoin clinic (median age: 22 years, range: 14–62 years, 40% male), soft papular scars of the nose and chin were noted in two patients (2%). Both were male, aged 23; one of whom had additional boxcar scars and the other had both boxcar and ice pick scars.

Baseline characteristics of the 49 patients with acne attending the general dermatology clinic showed a median age of 23 years (range: 14–48 years), 15 (31%) were male, median age of acne onset was 15, 21 (43%) had evidence of other acne scar variants, 31 (63%) had active acne and 39 (80%) were receiving or had received isotretinoin therapy. Of these patients, a 24-year-old female had soft papular scars over the chin and boxcar scars over the cheeks and a 19-year-old male also had soft papular scars on the nose, with no evidence of scarring elsewhere.

## DISCUSSION

To our knowledge, this is the first series of patients described and characterised with soft papular acne scars of the nose

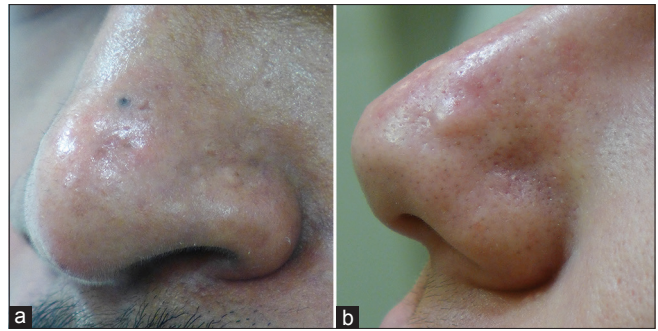

Figure 1: (a and b) Representative examples of papular acne scars of the nose

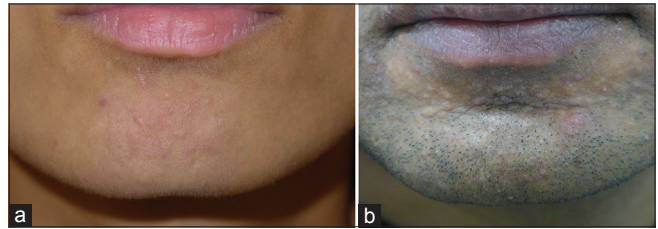


Figure 2: (a and b) Representative examples of papular acne scars of the chin

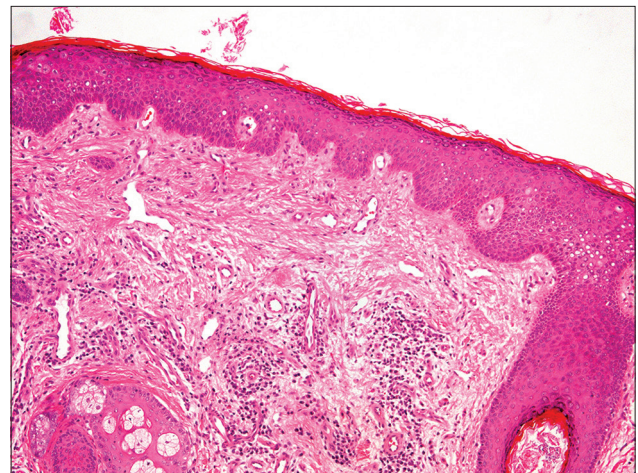


Figure 3: Histology of representative lesion on nose showing superficial dermal fibrosis, mild vascular ectasia and perivascular chronic inflammation (H and E, ×10)

and chin. There appears to be a distinct male proclivity and anatomical predilection for the nose and chin.

Post-acne scarring has been investigated in only a few studies.<sup>[6]</sup> One study of 185 patients in the UK suggests that up to 95% of patients with active acne have evidence of facial scarring.<sup>[4]</sup> A larger study of 973 patients suggested that 55% of patients have clinically relevant scarring on the face, 14% scarring on the chest and 24% scarring on the back.<sup>[7]</sup> The proportion of patients with scarring in our clinic appears to be lower (43%) than previously reported, in part attributable to different populations being sampled, who may be referred to

our clinic at an earlier stage, and perhaps owing to the subjective nature of scar assessment.

Papular scars as a distinct entity have been reported recently, but without description of individual patients, epidemiology or concurrent clinical features.<sup>[8]</sup> Our findings are in keeping with the previous authors' description of papular scars occurring most commonly on the nose and chin. Furthermore, we suggest that soft papular scars may occur more commonly in males and more frequently in individuals with other demonstrable acne scars. Previous descriptions of predominantly truncal papular acne scars (on the back)<sup>[9]</sup> are now more commonly recognised as elastolytic scars and are clinically and histologically distinct to the entity we are describing.

We hypothesise that pathogenesis of soft papular acne scars of the nose and chin is related to mismatch in the ratio of matrix metalloproteases (MMPs) to tissue inhibitors of MMPs produced by fibroblasts and keratinocytes during the scarring process that follows resolution of inflammatory acne.<sup>[10]</sup>

We acknowledge the difficulty in extrapolating epidemiological details of papular acne scars of the nose and chin from the cases we report, and that our data are partly dependent on our subjective judgement. While biopsy of all patients with papular scars is academically desirable, we feel that this may not always be in the clinical interest of our patients. In addition, insufficient time has elapsed to provide useful longitudinal data relating to the prognosis and effectiveness of treatment modalities for these scars.

We also acknowledge that patients referred to secondary or tertiary care dermatology clinics and those seeking treatment for acne scarring typically would have had acne recalcitrant to topical therapies or systemic antibiotics, so they may represent a more severe subgroup of patients. Furthermore, the patients reported are not representative of the global population of acne patients, as patients who are being seen depends upon those patients who actively seek treatment, the likelihood of primary care physicians to refer rather than a true cross-population sample.<sup>[3]</sup>

We have reported the first series of patients with papular acne scars of the nose and chin and proposed that this under-recognised stratum of acne scarring should be added to categorisation schemes. Future work should include corroborative investigation of epidemiology and pathophysiology and evaluation of the most effective treatment modalities.

## CONCLUSION

We have identified 18 new patients with papular acne scars of the nose and chin and propose that this new category should be added to acne scarring classification schemes. Future work should be directed at corroborating the epidemiology of such lesions and describing effective treatment modalities.

## Financial support and sponsorship

Nil.

## Conflicts of interest

There are no conflicts of interest.

## REFERENCES

1. Williams HC, Dellavalle RP, Garner S. Acne vulgaris. *Lancet* 2012;379:361-72.
2. Bhate K, Williams HC. Epidemiology of acne vulgaris. *Br J Dermatol* 2013;168:474-85.
3. Rivera AE. Acne scarring: A review and current treatment modalities. *J Am Acad Dermatol* 2008;59:659-76.
4. Layton AM, Henderson CA, Cunliffe WJ. A clinical evaluation of acne scarring and its incidence. *Clin Exp Dermatol* 1994;19:303-8.
5. Sánchez Viera M. Management of acne scars: Fulfilling our duty of care for patients. *Br J Dermatol* 2015;172 Suppl 1:47-51.
6. Tan JK, Bhate K. A global perspective on the epidemiology of acne. *Br J Dermatol* 2015;172 Suppl 1:3-12.
7. Tan JK, Tang J, Fung K, Gupta AK, Richard Thomas D, Sapra S, et al. Development and validation of a scale for acne scar severity (SCAR-S) of the face and trunk. *J Cutan Med Surg* 2010;14:156-60.
8. Gan SD, Graber EM. Papular scars: An addition to the acne scar classification scheme. *J Clin Aesthet Dermatol* 2015;8:19-20.
9. Wilson BB, Dent CH, Cooper PH. Papular acne scars. A common cutaneous finding. *Arch Dermatol* 1990;126:797-800.
10. Fabbrocini G, Annunziata MC, D'Arco V, De Vita V, Lodi G, Mauriello MC, et al. Acne scars: Pathogenesis, classification and treatment. *Dermatol Res Pract* 2010;2010:893080.