

Desire for Penile Girth Enhancement and the Effects of the Self-Injection of Hyaluronic Acid Gel

Penile girth enhancement is a controversial subject but demands for enhancement are increasing steadily. Although various fillers have been widely used for soft tissue augmentation, there is no reliable material for this particular situation. Here we report a case of an acute hypersensitivity reaction in a man after his first self-injection of a filler material, which, he claimed, was hyaluronic acid gel for penile girth enhancement and glans penis augmentation.

KEYWORDS: Aesthetic surgery, complication, penis augmentation

INTRODUCTION

The importance of minimal invasive cosmetological procedures is highlighted in almost all Aesthetic Surgery meetings with an impressive statistical graphing showing the steady increase in the frequency of these procedures each year and growing up of the financial profits in this market. Not only medical professionals but also the ordinary people are now well aware of these procedures. All these procedures have been presented as 'lunch time procedures for beauty' in order to increase their attractiveness in public.

All these commercial manoeuvres, on the other hand, ended up with the underestimation of these procedures by the ordinary people. In addition to specialists such as plastic surgeons and dermatologists, after few week courses, some general practitioners and in some countries even the people without any medical background begun to perform these minimal invasive cosmetological procedures under the name of medical cosmetologists or cosmeticians.

There are plenty of brand names for the botulinum toxins and the filling materials. The supplier companies, on

the other hand, inform the physicians as user that the dosage units or the concentrations of different products do not relate to each other. In other words, these products supplied from different manufacturers cannot be used interchangeably with each other even if they contain the same active ingredient. Therefore, users are supposed to get experience from their own practice for every product they use.

Furthermore, the manufacturer companies of these products are supervised by different regulatory institutions of the countries where the product is manufactured. Therefore, it is hard to say that the regulatory rules about their production are standard all around the world. As a result, the quality of the filling materials is not standard.

Penile girth enhancement is a controversial subject but demands for enhancement are increasing steadily.^[1] Although various fillers have been used widely for soft tissue augmentation, there is no reliable material as filler for penile soft tissue.

The soft tissue fillers are supposed to be nontoxic and nonimmunogenic. Because of their composition and biochemical characteristics, however, they may act as a foreign body in the tissue, eliciting host response or may be associated with severe allergic reactions.^[2-4]

We report a case of an acute hypersensitivity reaction in a man after his first self-injection of hyaluronic acid gel for penile girth enhancement and glans penis augmentation.

Access this article online	
Quick Response Code: 	Website: www.jcasonline.com
	DOI: 10.4103/0974-2077.101382

Enis Rauf Coskuner, Halil Ibrahim Canter¹

Departments of Urology, ¹Plastic and Reconstructive Surgery, Acibadem School of Medicine, Istanbul, Turkey

Address for correspondence:

Enis Rauf Coskuner, Department of Urology, Acibadem University School of Medicine, Acibadem Health Group, Acibadem Bakirkoy Hospital, Halit Ziya Usakligil Cad. No:1, Bakirkoy 34140, Istanbul, Turkey. E-mail: enisraufcoskuner@hotmail.com

CASE REPORT

A 37-years-old man was admitted to our hospital with an adverse reaction in his penis after self-injection of hyaluronic acid gel in the last 24 h. The patient declared that he got the injected material from an internet-based supplier after a google- -search with the keyword 'hyaluronic acid'. He had decided to inject this material into his penile skin and glans penis after his own search in the medical literature on internet. Although it was questioned, the patient did not inform us either about the brand name of the product or where he found it. The patient developed indurated and erythematous nodules on the entire penile shaft, glans penis and scrotum [Figure 1a]. In his penile and scrotal ultrasonographic examination, soft tissue inflammation and suspicion of venous occlusion were reported. He was hospitalized and followed- -up conservatively with intravenous prophylactic antibiotics, non--steroidal anti--inflammatory drugs for the management of pain and oedema and anti-aggregant drugs for treatment of possible venous occlusion. We offered but he refused psychiatric evaluation. After 3 days of the hospital stay, he was discharged and followed up in our out-patient clinic. All the skin reactions were settled down and he had no erectile dysfunction after 2 weeks [Figure 1b].

DISCUSSION

The American Society for Aesthetic Plastic Surgery 2010 statistics on cosmetic surgery emphasized the steady increase in the frequency of minimal invasive cosmetological procedures as a result of increasing public awareness.^[5] Many of these products work very well for people, but they should be used appropriately by qualified physicians who understand the intricacies of the medications used and how to combat with complications that may arise. Even if advertising about drugs and medical procedures are prohibited by law in some countries, through the internet banners on popular web pages or via spam mails, the information about the procedures and the commercials of these products are still distributed freely. Disturbing stories arising from all around the world tell us that there is an unsafe climate for patients looking to enhance their appearance with non-invasive procedures with lower prices in the current economy.^[6] There is undebatable growing need for physicians to be properly trained to respond to adverse events.

A Google search with the brand name of the well-known hyaluronic acid filler ends up with more than 4 million web pages. Some of these web pages distribute the uncontrolled wrong information about the dermal fillers and soft tissue augmentation procedure. Some others are designed to market these products on internet. Easy accessibility of these products, increased popularity of

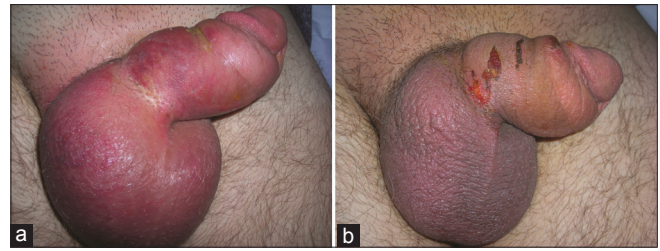


Figure 1: (a) Appearance of the penis before the treatment. (b) Appearance of the penis after the treatment

such procedures and the underestimation of the possible risks of the procedures resulted in a rise in illegal injections with dangerous, non-branded, non-approved or unsafe substances used by unlicensed or unqualified people or even by patients themselves.

Penile size is a big problem in many men's mind. A man is often troubled by concerns that his penis is not large enough to satisfy his partner or himself. He is ashamed to have others view his penis, especially in the flaccid state. Such concerns might be unfounded in reality and might be a presentation of social anxiety or some other clinical problem, such as erectile dysfunction. The effects of media and internet usage make this problem more serious.^[7]

Most men who request for penis enlargement have a normal-sized and fully functional penis but visualize their penises as small. Most patients who seek appearance-enhancing medical treatments report some degree of body image dissatisfaction, which is believed to motivate the pursuit of these treatments. However, patients with extreme body image dissatisfaction may be suffering from a psychiatric disorder known as body dysmorphic disorder (BDD), which is a serious disorder of body perception. Although patients with BDD frequently seek cosmetic treatments to address their appearance-related distress, such treatments are rarely beneficial.^[8]

There are other sporadic cases of self-induced subcutaneous injected substances, such as liquid paraffin, cod liver oil, metallic mercury or mineral oil into the urogenital region in the literature mainly for the purpose of penis enlargement.^[9-13]

Despite the debates on penis augmentation, demands for enhancement are increasing. Surgical procedures and various fillers are being used widely. Vardi *et al* performed an extensive systematic review based on a search of 34 selected articles and concluded that the use of cosmetic surgery to enlarge the penis remains highly controversial. There is a lack of any standardization of all described procedures. Indications and outcome measures are poorly defined, and the reported complications, such as penile deformity, paradoxical penile shortening, disagreeable

scarring, granuloma formation, migration of injected material, and sexual dysfunction, are unacceptably high.^[14]

Kwak et al aimed to identify the feasibility and efficacy of penile girth enhancement by injection of hyaluronic acid gel. A total of 50 patients with subjective small penises were enrolled and prospectively followed for 18 months. There were no inflammatory signs or serious adverse reactions in all cases. According to their follow-up results they concluded that penile girth enhancement is a very effective and safe technique for penile augmentation.^[1]

Therefore, although some data have been accumulated for hyaluronic acid gel as penile soft tissue filler, there is no evidence-based clinical guideline for dermal fillers for penile augmentation yet. Long-term data are still required before a general consensus can be reached. Recent findings point to the absolute need for a thorough psychological assessment of men requesting penile enhancement procedures. Physicians who perform the penile augmentation procedure should work in a very close collaboration with psychologists before the procedure and afterwards. This will verify the eligibility for surgery and counselling.

REFERENCES

1. Kwak TI, Oh M, Kim JJ, Moon DG. The effects of penile girth enhancement using injectable hyaluronic acid gel, a Filler. *J Sex Med* 2010;8:3407-13.
2. Lupton JR, Alster TS. Cutaneous hypersensitivity reaction to injectable hyaluronic acid gel. *Dermatol Surg* 2000;26:135-7.
3. Bardazzi F, Ruffato A, Antonucci A, Balestri R, Tabanelli M. Cutaneous granulomatous reaction to injectable hyaluronic acid gel: Another case. *J Dermatolog Treat* 2007;18:59-62.
4. Ghislanzoni M, Bianchi F, Barbareschi M, Alessi E. Cutaneous granulomatous reaction to injectable hyaluronic acid gel. *Br J Dermatol* 2006;154:755-8.
5. Available from: http://www.surgery.org/sites/default/files/2010-quickfacts_0.pdf [Last accessed on 2012 Feb 01].
6. Available from: http://www.injectablesafety.org/media/news_release/36 [Last accessed on 2012 Feb 01].
7. Kamel I, Gadalla A, Ghanem H, Oraby M. Comparing penile measurements in normal and erectile dysfunction subjects. *J Sex Med* 2009;6:2305-10.
8. Sarwer DB, Crerand CE, Magee L. Body dysmorphic disorder in patients who seek appearance-enhancing medical treatments. *Oral Maxillofac Surg Clin North Am* 2010;22:445-53.
9. Akkus E, Iscimen A, Tasli L, Hattat H. Paraffinoma and ulcer of the external genitalia after self-injection of vaseline. *J Sex Med* 2006;3:170-2.
10. Nyirady P, Kelemen Z, Kiss A, Banfi G, Borka K, Romics I. Treatment and outcome of vaseline-induced sclerosing lipogranuloma of the penis. *Urology* 2008;71:1132-7.
11. Al-Ansari AA, Shamsodini A, Talib RA, Gul T, Shokeir AA. Subcutaneous cod liver oil injection for penile augmentation: Review of literature and report of eight cases. *Urology* 2010;75:1181-4.
12. Oh KJ, Park K, Kang TW, Kwon DD, Ryu SB. Subcutaneous metallic mercury injection for penile augmentation. *Urology* 2007;69:185.e3-4.
13. Hohaus K, Bley B, Köstler E, Schönlebe J, Wollina U. Mineral oil granuloma of the penis. *J Eur Acad Dermatol Venereol* 2003;17:585-7.
14. Vardi Y, Har-Shai Y, Gruenwald I. A critical analyses of penile enhancement procedures for patients with normal penile size: Surgical techniques, success, and complications. *Eur Urol* 2008;54:1042-50.

How to cite this article: Coskuner ER, Canter HI. Desire for penile girth enhancement and the effects of the self-injection of hyaluronic acid gel. *J Cutan Aesthet Surg* 2012;5:198-200.

Source of Support: Nil. **Conflict of Interest:** None declared.