

Management of stretch marks (with a focus on striae rubrae)

Uwe Wollina, Alberto Goldman¹

Department of Dermatology and Allergology, Academic Teaching Hospital Dresden, Dresden, Germany, ¹Clinica Goldman, Porto Alegre/ RS, Brazil

Abstract

Stretch marks are one of the most common benign cutaneous lesions and encountered esthetic problems. Striae rubrae and striae albae can be differentiated on the basis of clinical appearance. Histologically, disturbances of the dermal fiber network and local expression of receptors for sexual steroids have been detected. The epidermal changes are secondary. Prevention of stretch marks using topical ointments and oils is debatable. Treatment of striae rubrae by lasers and light devices improves appearance. Microneedling and non-ablative and fractionated lasers have been used. This review provides an overview on current treatment options with a special focus on laser treatments.

Keywords: Lasers, stretch marks, striae albae, striae rubrae, therapy

INTRODUCTION

Stretch marks or striae distensae (syn. striae gravidarum) are common cutaneous adverse reactions caused during pregnancy affecting approximately 50–90% of pregnant women. Stretch marks are seen in other conditions as well, such as rapid weight gain (obesity), muscle hypertrophy (bodybuilders), endocrinopathies (such as Cushing syndrome), breast augmentation, or as a side effect of topical corticosteroid use and abuse. They are a rare complication when using tissue expanders. Stretch marks are most commonly seen on thighs, abdomen, female breasts, and upper arms in males.^[1-6]

In pregnant women, independent predictors of stretch marks have been identified: Younger age, maternal and family history of stretch marks, increased pre-pregnancy and predelivery weight, increased birth weight, and the absence of chronic disease.^[7-9] In pregnant women, itching stretch marks may be a sign of herpes gestationis.^[10]

Histological studies argue for a primary disruption of the normal elastic fiber network. Instead of normal fibrils, short, disorganized, thin, threadlike fibrils emerge in the mid-to-deep dermis. These fibrils are rich in tropoelastin and persist into the postpartum period without forming normal-appearing elastic fibers. This is accompanied by increased gene expression of tropoelastin and fibrillin-1.^[11]

The disruption of elastin fiber network results in changes in viscoelastic properties of affected skin, which is significantly less firm, less elastic, and less deformable than normal skin. Light scattering values are significantly lower in stretch marks compared to adjacent skin. Scattering values suggest an altered collagen fiber structure in the dermis with parallel collagen bundles.^[12] No difference was observed in skin barrier function and a slight difference was observed in skin hydration between the stretch marks and uninvolved skin. Diffuse reflectance spectroscopy showed no differences in the apparent hemoglobin concentrations between stretch marks and controls.^[13] Skin pigmentation is significantly lower in stretch marks compared to adjacent skin.^[12]

Immunohistochemical studies suggested a significant increase of estrogen, androgen, and glucocorticoid receptors in stretch marks.^[14] Pregnant women with stretch marks have lower serum relaxin levels compared to those without stretch marks at 36th gestational week, 330.8 ± 175.2 vs. 493.8 ± 245.8 pg/mL ($P = 0.037$). However, there is no correlation between the severity of stretch marks and serum relaxin levels.^[15]

Address for correspondence: Uwe Wollina, MD,

Department of Dermatology and Allergology, Academic Teaching Hospital Dresden, Friedrichstr. 41, 01067 Dresden, Germany.
E-mail: wollina-uw@khdf.de

Access this article online

Quick Response Code:



Website:
www.jcasonline.com

DOI:
10.4103/JCAS.JCAS_118_17

This is an open access article distributed under the terms of the Creative Commons Attribution-NonCommercial-ShareAlike 3.0 License, which allows others to remix, tweak, and build upon the work non-commercially, as long as the author is credited and the new creations are licensed under the identical terms.

For reprints contact: reprints@medknow.com

How to cite this article: Wollina U, Goldman A. Management of stretch marks (with a focus on striae rubrae). *J Cutan Aesthet Surg* 2018;10:124-9.

There is a characteristic feature of maturation of stretch marks, which emerge as striae rubrae but eventually shift to striae albae. Although striae rubrae are erythematous, sometimes edematous, striae albae are depressed atrophic scars with wrinkling surface.

Treatment targets are dermal collagen production, vascularity (in striae rubrae), wrinkling, and roughness of skin.^[16]

AVAILABLE TREATMENTS

Prevention of stretch marks

A number of topical treatments has been advertised for the prevention of stretch marks. In a critical review, Korgavkar and Wang^[17] concluded that there is limited evidence that centella, and possibly massage with bitter almond oil, may prevent stretch marks. Weak evidence is present for the use of topical hyaluronic acid. A controlled trial with olive oil and Saj® cream demonstrated that neither of these interventions could prevent stretch marks during pregnancy.^[18] Other authors came to the conclusion that topical treatments are unable to prevent stretch marks.^[19-21]

Reduction of severity of stretch marks with non-laser approaches

In general, early stretch marks, i.e., striae rubrae, respond better to treatment than the older lesions, i.e., striae albae. Therefore, we focus on early stretch marks unless otherwise mentioned.

A randomized, double-blind, placebo-controlled study in pregnant women indicates that the severity of stretch marks can be reduced by topical application of emollient and moisturizer containing hydroxyprolisilane C, rose hip oil, *Centella asiatica* triterpenes, and vitamin E.^[22] It seems that moisturizers are the critical component of topical preparations for the treatment of stretch marks and it is questionable, if there is an add-on effect of other ingredients.^[23]

In a prospective randomized open trial, microdermabrasion was found to be as effective as the daily application of topical 0.05% tretinoin cream in the reduction in the severity of early stretch marks.^[24] Microdermabrasion in combination with topical platelet-rich plasma was found to be more effective in reducing stretch mark severity than the single component.^[25] To enhance penetration of topical tretinoid cream, ablative radiofrequency was combined with ultrasound. In a pilot trial, striae albae improved by this combined approach.^[26]

In a pilot study with 16 females, noninvasive multipolar-pulsed electromagnetic field and radiofrequency energy-generating treatment resulted in some improvement in the length and widths of stretch marks.^[27]

Microneedling improved early and late stretch marks in a pilot study carried out among Korean women.^[28] This is

substantiated by a study performed in South Africa and Germany with one to four treatments.^[29] Microneedling therapy was more efficient than microdermabrasion with phonophoresis in the treatment of stretch marks.^[30]

A pilot study with tripolar radiofrequency device for 1 week suggested a reduction in the severity of stretch marks in women.^[31]

In a comparative trial, 22 men and women with abdominal striae were included. The abdomen was divided into four equal quadrants. Bipolar radiofrequency potentiated with infrared light and fractional bipolar radiofrequency were applied, alone or in combination, and one quadrant was left untreated. Of the 384 striae that were measured, the mean depth was decreased by 21.6% at 6 month follow-up with the combined approach. The width of stretch marks was not affected by any treatment. Histologically, thicker collagen fibers were noted after treatment.^[32]

All these studies support the fact that any type of controlled damage or lesion mainly in early striae can improve their aspect. They also support our results using laser energy as alternative in the treatment.

LASER-BASED TREATMENTS

Several treatments have been proposed in an attempt to obtain esthetic improvement of striae. Depending on their extent, location, and the personal perception of the patients, stretch marks may cause great esthetic dissatisfaction and have a profound negative impact on their self-esteem. Laser therapy has represented a breakthrough in the approach to striae, in particular striae rubrae.

The natural course of stretch marks argues for an increased vascularity in the early lesions (striae rubrae). Hence, here, vascular lasers should have a beneficial effect, as hemoglobin is working as a chromophore for specific lasers acting in this vascularity.

The 585-nm pulsed dye laser with a 10-mm spot size using 3.0 J/cm² fluence improved the appearance of striae in a small study. Histologic evaluation argued for the restoration of normal elastin fiber network.^[33] The effect has been scored as moderate for striae rubrae, but there is no beneficial effect on striae albae.^[34] Other groups observed some beneficial effects using the flashlamp-pumped pulsed dye laser (585 nm). Striae width was decreased and skin texture was improved. Collagen expression was increased with the exception of collagen I.^[35] In ethnic skin (skin types 4–6), such treatment should be avoided because of the risk of permanent pigmentary changes.^[36]

The copper bromide laser (577–511 nm) has been evaluated in an Italian pilot trial for female patients, Fitzpatrick phototype II–III, with a 2-year follow-up. The authors described a mild beneficial clinical and histologic effect on stretch marks.^[37]

Three treatments carried out 6 weeks apart with a 1450-nm diode laser, 6-mm spot size, fluence between 4 and 12 J/cm², and dynamic cooling device, to protect the epidermis, did not result in any improvement of stretch marks.^[38]

A trial with the 1064-nm long-pulsed neodymium-doped yttrium aluminium garnet (Nd:YAG) laser, spot size of 2.5 mm, fluence of 80–100 J/cm², and a frequency of 2 Hz in 20 patients with striae rubrae resulted in excellent results in 40% (physician's assessment) and 55% (patient's assessment) [Figures 1-4]. The average number of treatments carried out 3 to 6 weeks apart was 3.5. Observed side effects were mild and temporary such as minimal edema and erythema, which lasted from a few hours to a maximum of 3 days.^[39]

In a trial with 45 patients, efficacies of two fluences (75 and 100 J/cm²) of long-pulsed Nd:YAG laser on stretch marks were compared. Spot size was 5 mm, pulse duration was 15 ms. Clinical and histological evaluation was performed 3 months after treatment. A significant improvement in the appearance of striae albae was seen with 100 J/cm² fluence, whereas striae rubrae showed a better improvement with 75 J/cm². Histologically, the dermal content of both collagen and elastin fibers increased.^[40]

A trial comparing the efficacy of 1064-nm long-pulsed Nd:YAG laser and 2940-nm variable square pulse erbium yttrium aluminium garnet (Er:YAG) laser in the treatment of striae albae could produce histological improvement but no significant clinical improvement with either treatment modalities.^[41] A variable square pulse Er:YAG laser resurfacing was performed in 21 women of Fitzpatrick phototype ≥III with short pulse or smooth mode twice with an interval of 4 weeks in between. Skin roughness, skin smoothness, and surface of stretch marks improved by both the modes. An adverse event in ethnic skin is hyperpigmentation lasting as long as half a year.^[42]

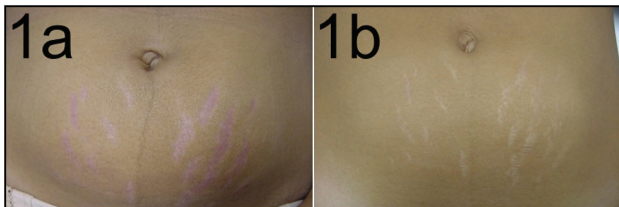


Figure 1: Striae gravidarum in the abdomen. Before (a) and after (b) single session of 1064-nm long-pulsed Nd:YAG laser

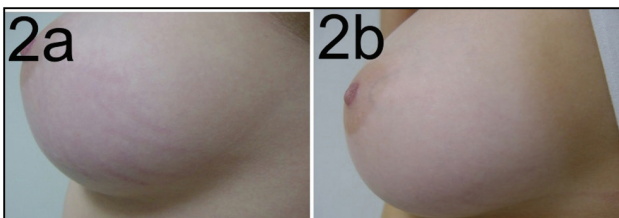


Figure 2: Stretch marks in the breast in a 17-year-old patient. Before (a) and after (b) two sessions of 1064-nm long-pulsed Nd:YAG laser

The 2940-nm Er:YAG ablative fractional laser can be combined with other treatment modalities to improve striae albae. In a study with 30 females with stretch marks, ablative laser was applied 6 times at 4-week intervals. This treatment was followed by topical application of recombinant bovine basic fibroblast growth factor for 1 week. This was followed by red light-emitting diode once every week for three sessions between the two laser treatments. Clinical improvement was noted for up to 12 months posttreatment. Post-procedural skin biopsies demonstrated an increase in epidermal and dermal thickness, collagen, and elastin density compared to baseline.^[43]

In a comparative trial, patients with striae albae treated with either 1550-nm fractional Er:glass laser or ablative fractional CO₂ laser achieved clinical and histologic improvement.^[44] A smaller group of patients with striae rubrae after breast augmentation also benefited from the 1550-nm Er:glass laser.^[45]

Treatment of stretch marks in Asian women with a 1550-nm fractional laser improved stretch marks clinically. Skin elasticity was found to be partially normalized. Skin biopsies argued for a significant increase in epidermal thickness, collagen, and elastic fiber deposition after fractional laser therapy. Adverse effects included mild and transient pain and hyperpigmentation.^[46] The Er-doped fractionated 1550-nm laser has been recommended for the treatment of stretch marks in a consensus conference.^[47]

Ten women with stretch marks (striae albae) and Fitzpatrick skin types III–V were treated with non-ablative 1540-nm fractional laser four times at 4-week intervals. The fluence was 50–70 J/cm². There was a clinically appreciable improvement in striae ranging from 1% to 24%. Three months after the final treatment, patients showed noticeable improvement in the striae, when compared with baseline. Mild post-inflammatory hyperpigmentation was observed in a single patient.^[48] This laser type has also been

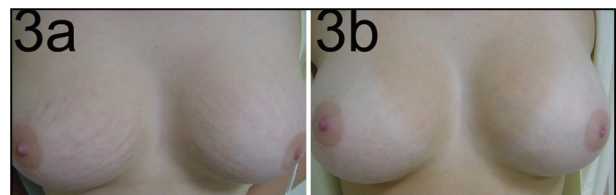


Figure 3: Breast striae after cosmetic augmentation. Before (a) and after (b) two sessions of 1064-nm long-pulsed Nd:YAG laser

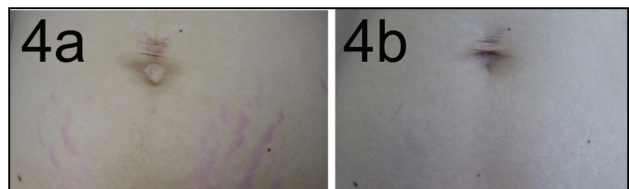


Figure 4: Stretch marks in the abdominal region. Before (a) and after (b) two sessions of 1064-nm long-pulsed Nd:YAG laser

used successfully in patients with stretch marks because of topical corticosteroids.^[49]

A non-ablative fractional 1565-nm laser was used in 12 Caucasian patients with stretch marks. All participants achieved three treatments. Good clinical improvement (between 51% and 75%) was observed in all patients. Most patients showed improvement in the volume of depressions and in lesion color. The average downtime was 4 days.^[50]

A small study compared non-ablative fractionated lasers of 1540 and 1410 nm. Nine patients were treated with six laser sessions with intraindividual comparison. In all patients, a clinical improvement was seen. Histologically, increased epidermal and dermal thickness, and collagen and elastin density were seen compared to baseline. Clinical and histopathological differences between the two wavelengths were comparable.^[51]

A non-fractional 1550-nm laser was used for the treatment of abdominal striae rubrae and striae albae in 16 females. They were treated with five sessions at 1-month intervals. The mean width and length of striae decreased with a more pronounced effect on length. There was a further improvement from 1 month after treatment to 1 year follow-up.^[52]

Fractional 10,600-nm CO₂ laser was effective in striae albae in patients of skin type III and IV. The laser parameters were as follows: fluence 16 J/cm², dot cycle 2, pixel pitch 0.8 mm. The treatment was performed in five sessions with two passes, 2 to 4 weeks apart. The clinical improvement was significantly better than topical treatment with 0.05% tretinoin cream and 10% glycolic acid peels.^[53]

In a pilot trial, 44 striae albae were treated with a combined approach using fractional CO₂ laser and pulsed dye laser and compared to 44 lesions treated with fractional

CO₂ laser only. The investigators scored the efficacy of combined treatment as higher without any increase in unwanted side effects.^[54]

In another trial, 40 patients with stretch marks were treated with fractional CO₂ laser or intense pulse light. The CO₂ laser worked faster and was more effective.^[55]

In our opinion, the fractional CO₂ laser represents the first option in the treatment of striae albae. Unfortunately, the results are poor and the improvement very limited. We also use Er:YAG laser here, but the results are limited and the redness aspect consequent to laser action lasts a very long period.

Limited experience exists with the use of fractional Er:YAG laser.^[56]

In conclusion, laser therapy of early stretch marks (striae rubrae) targets vessels. The treatment of early and later (striae albae) stretch marks aims to increase collagen production, restore elastin fibers, and epidermal thickness. Skin texture improvements also contribute to clinical effects of laser therapy.^[57-60] The number of studies with at least 20 patients is limited, and placebo-controlled studies have not been published [Table 1].

DISCUSSION

Stretch marks are common. They can affect both men and women, but are more frequent among women. Although they rarely cause medical problems, stretch marks are considered a major esthetic concern and have negative impact on self-esteem and quality of life of an individual.^[1,5]

The typical appearance of early stretch marks is redness and some edema, whereas matured stretch marks are linear type of atrophic scars. The clinical response to any treatment is better in early stretch marks.

Table 1: Laser therapy of stretch marks (studies with at least 20 patients included)

Laser type	Comparison	Study type	N	Outcome	Reference
585-nm pulsed dye	IPL	Side by side	20	Improvement better in striae rubrae both treatments effective	Shokeir <i>et al.</i> 2014
585-nm pulsed dye with Thermage		Open	37	89.2% of patients rated the outcome "good" or better	Suh <i>et al.</i> 2007
585-nm pulsed dye		Open	20	Moderate beneficial effect on striae rubrae	Jiménez <i>et al.</i> 2003
1,064-nm long-pulsed Nd:YAG		Open	20	55% of patients rated the outcome "excellent"	Goldman <i>et al.</i> 2008
1,064-nm long-pulsed Nd:YAG		Open	45	Significant improvement in appearance	Elsaie <i>et al.</i> 2016
1,540-nm Er:glass		Open	51	≥50% improvement for all patients after 6 months	de Angelis <i>et al.</i> 2011
1,550-nm Er-doped fractional		Open	20	Moderate improvement in 63% of patients	Stotland <i>et al.</i> 2008
2,940-nm variable square pulsed Er:YAG-		Open	21	Significant volume reduction of stretch marks after 6 months	Wanithakdeedecha <i>et al.</i> 2017
10,600-nm CO ₂ fractional		Retrospective	27	Improvement after a single treatment	Lee <i>et al.</i> 2010
10,600-nm CO ₂ fractional	IPL	Open	40	Improvement better than with pulsed light	El Taieb and Ibrahim 2016

IPL = Intense pulsed light

Topical treatments have only mild effects. It is questionable, if creams and ointments with “specific ingredients” exert a significant and better improvement than moisturizers. Topical treatment cannot prevent the occurrence of stretch marks under specific circumstances such as pregnancy.^[116-23]

Laser treatment is a physical tool used in the improvement of stretch marks with a focus on early stretch marks [Table 1]. Owing to its physical characteristics, represented mainly by the 1064-nm wavelength and dye pumped laser, these lasers are very safe. Complications are rarely produced when the device and parameters are appropriately utilized, even in patients with dark skin. In addition, the cooling of the striae before and immediately after the use of the laser represents yet another factor in epidermal protection. Such cooling of the treated areas, however, should not be too long so as to avoid local vasoconstriction and the consequent decrease of the chromophore oxyhemoglobin. The treatment of erythematous striae using the 1064-nm long-pulsed Nd:YAG laser demonstrated clinical improvement of such lesions, probably due to the laser’s affinity toward the vascular target present in the striae. The absorption of the laser by its target, i.e., oxyhemoglobin, leads to an improvement in the redness. In addition, it has become evident that, like other luminous sources, the long-pulsed Nd:YAG laser also induces the formation of new collagen; this leads to an improvement in the atrophy of the skin and consequently, improves the appearance of immature striae. This improvement was evident for both the patients and doctors.^[35,39] The full clearance of the lesions is very rare and seems to be occasionally obtained in some isolated areas of recent striae. Hence, it is vital to start the treatment as early as possible.

Declaration of patient consent

The authors certify that they have obtained all appropriate patient consent forms. In the form the patient(s) has/have given his/her/their consent for his/her/their images and other clinical information to be reported in the journal. The patients understand that their names and initials will not be published and due efforts will be made to conceal their identity, but anonymity cannot be guaranteed.

REFERENCES

- Piérard-Franchimont C, Peters S, Hermanns JF, Lesuisse M, Saint-Léger D, Piérard GE. Striae distensae, colors and mechanobiology. *Rev Med Liege* 2014;69:151-4.
- Wollina U, Dreßler M, Lohmann T. Bariatric surgery - A dermatologic perspective. *J Eur Acad Dermatol Venereol* 2015;29:835-41.
- Wollina U, Pabst F, Schönlebe J, Abdel-Naser MB, Konrad H, Gruner M, *et al.* Side-effects of topical androgenic and anabolic substances and steroids. A short review. *Acta Dermatovenerol Alp Pannonica Adriat* 2007;16:117-22.
- Tsai TL, Castillo AC, Moliver CL. Breast striae after cosmetic augmentation. *Aesthet Surg J* 2014;34:1050-8.
- Valente DS, Zanella RK, Doncatto LF, Padoin AV. Incidence and risk factors of striae distensae following breast augmentation surgery: A cohort study. *PLoS One* 2014;9:e97493.
- Chan WY, Akhtar S, Phipps AR. Striae distensae in tissue-expanded skin in the upper arm. *Ann Plast Surg* 2006;57:240-1.
- Farahnik B, Park K, Kroumpouzou G, Murase J. Striae gravidarum: Risk factors, prevention, and management. *Int J Womens Dermatol* 2017;3:77-85.
- Kasielska-Trojan A, Sobczak M, Antoszewski B. Risk factors of striae gravidarum. *Int J Cosmet Sci* 2015;37:236-40.
- Chikvaidze N, Kristesashvili J, Gegechkori M. Peculiarities of sexual development and reproductive function in young women with childhood onset weight problems. *Georgian Med News* 2014;235:11-6.
- Wollina U, Degen KW, Konrad H, Schönlebe J. Itching stretch marks and bullous lesions in a pregnant woman. *Int J Dermatol* 2004;43:752-4.
- Wang F, Calderone K, Smith NR, Do TT, Helfrich YR, Johnson TR, *et al.* Marked disruption and aberrant regulation of elastic fibers in early striae gravidarum. *Br J Dermatol* 2015;173:1420-30.
- Stamatas GN, Lopes-DaCunha A, Nkengne A, Bertin C. Biophysical properties of striae distensae evaluated *in vivo* using non-invasive assays. *Skin Res Technol* 2015;21:254-8.
- Bertin C, Lopes-DaCunha A, Nkengne A, Roure R, Stamatas GN. Striae distensae are characterized by distinct microstructural features as measured by non-invasive methods *in vivo*. *Skin Res Technol* 2014;20:81-6.
- Cordeiro RC, Zecchin KG, de Moraes AM. Expression of estrogen, androgen, and glucocorticoid receptors in recent striae distensae. *Int J Dermatol* 2010;49:30-2.
- Lurie S, Matas Z, Fux A, Golan A, Sadan O. Association of serum relaxin with striae gravidarum in pregnant women. *Arch Gynecol Obstet* 2011;283:219-22.
- Hague A, Bayat A. Therapeutic targets in the management of striae distensae: A systematic review. *J Am Acad Dermatol* 2017;77:559-568.e18.
- Korgavkar K, Wang F. Stretch marks during pregnancy: A review of topical prevention. *Br J Dermatol* 2015;172:606-15.
- Soltanipour F, Delaram M, Taavoni S, Haghani H. The effect of olive oil and the saj® cream in prevention of striae gravidarum: A randomized controlled clinical trial. *Complement Ther Med* 2014;22:220-5.
- Al-Himdani S, Ud-Din S, Gilmore S, Bayat A. Striae distensae: A comprehensive review and evidence-based evaluation of prophylaxis and treatment. *Br J Dermatol* 2014;170:527-47.
- McAvoy BR. No evidence for topical preparations in preventing stretch marks in pregnancy. *Br J Gen Pract* 2013;63:212.
- Brennan M, Young G, Devane D. Topical preparations for preventing stretch marks in pregnancy. *Cochrane Database Syst Rev* 2012;11:CD000066.
- García Hernández JA, Madera González D, Padilla Castillo M, Figueras Falcón T. Use of a specific anti-stretch mark cream for preventing or reducing the severity of striae gravidarum. Randomized, double-blind, controlled trial. *Int J Cosmet Sci* 2013;35:233-7.
- Rawlings AV, Bielfeldt S, Lombard KJ. A review of the effects of moisturizers on the appearance of scars and striae. *Int J Cosmet Sci* 2012;34:519-24.
- Hexsel D, Soirefmann M, Porto MD, Schilling-Souza J, Siega C, Dal’Forno T. Superficial dermabrasion versus topical tretinoin on early striae distensae: A randomized, pilot study. *Dermatol Surg* 2014;40:537-44.
- Ibrahim ZA, El-Tatawy RA, El-Samony MA, Ali DA. Comparison between the efficacy and safety of platelet-rich plasma vs. microdermabrasion in the treatment of striae distensae: Clinical and histopathological study. *J Cosmet Dermatol* 2015;14:336-46.
- Issa MC, de Brito Pereira Kassuga LE, Chevrant NS, do Nascimento Barbosa L, Luiz RR, Pantaleão L, *et al.* Transepidermal retinoic acid delivery using ablative fractional radiofrequency associated with acoustic pressure ultrasound for stretch marks treatment. *Lasers Surg Med* 2013;45:81-8.
- Dover JS, Rothaus K, Gold MH. Evaluation of safety and patient subjective efficacy of using radiofrequency and pulsed magnetic fields for the treatment of striae (stretch marks). *J Clin Aesthet Dermatol* 2014;7:30-3.

28. Park KY, Kim HK, Kim SE, Kim BJ, Kim MN. Treatment of striae distensae using needling therapy: A pilot study. *Dermatol Surg* 2012;38:1823-8.
29. Aust MC, Fernandes D, Kolokythas P, Kaplan HM, Vogt PM. Percutaneous collagen induction therapy: An alternative treatment for scars, wrinkles, and skin laxity. *Plast Reconstr Surg* 2008;121:1421-9.
30. Nassar A, Ghomey S, El Gohary Y, El-Desoky F. Treatment of striae distensae with needling therapy versus microdermabrasion with sonophoresis. *J Cosmet Laser Ther* 2016;18:330-4.
31. Manuskiatti W, Boonthaweeyuwat E, Varothai S. Treatment of striae distensae with a tripolar radiofrequency device: A pilot study. *J Dermatolog Treat* 2009;20:359-64.
32. Harmelin Y, Boineau D, Cardot-Leccia N, Fontas E, Bahadoran P, Becker AL, *et al.* Fractionated bipolar radiofrequency and bipolar radiofrequency potentiated by infrared light for treating striae: A prospective randomized, comparative trial with objective evaluation. *Lasers Surg Med* 2016;48:245-53.
33. McDaniel DH, Ash K, Zukowski M. Treatment of stretch marks with the 585-nm flashlamp-pumped pulsed dye laser. *Dermatol Surg* 1996;22:332-7.
34. Jiménez GP, Flores F, Berman B, Gunja-Smith Z. Treatment of striae rubra and striae alba with the 585-nm pulsed-dye laser. *Dermatol Surg* 2003;29:362-5.
35. Shokeir H, El Bedewi A, Sayed S, El Khalafawy G. Efficacy of pulsed dye laser versus intense pulsed light in the treatment of striae distensae. *Dermatol Surg* 2014;40:632-40.
36. Nouri K, Romagosa R, Chartier T, Bowes L, Spencer JM. Comparison of the 585 nm pulse dye laser and the short pulsed CO₂ laser in the treatment of striae distensae in skin types IV and VI. *Dermatol Surg* 1999;25:368-70.
37. Longo L, Postiglione MG, Marangoni O, Melato M. Two-year follow-up results of copper bromide laser treatment of striae. *J Clin Laser Med Surg* 2003;21:157-60.
38. Tay YK, Kwok C, Tan E. Non-ablative 1,450-nm diode laser treatment of striae distensae. *Lasers Surg Med* 2006;38:196-9.
39. Goldman A, Rossato F, Prati C. Stretch marks: Treatment using the 1,064-nm nd:YAG laser. *Dermatol Surg* 2008;34:686-91.
40. Elsaie ML, Hussein MS, Tawfik AA, Emam HM, Badawi MA, Fawzy MM, *et al.* Comparison of the effectiveness of two fluences using long-pulsed nd:YAG laser in the treatment of striae distensae. Histological and morphometric evaluation. *Lasers Med Sci* 2016;31:1845-53.
41. Güngör S, Sayilgan T, Gökdemir G, Ozcan D. Evaluation of an ablative and non-ablative laser procedure in the treatment of striae distensae. *Indian J Dermatol Venereol Leprol* 2014;80:409-12.
42. Wanitphakdeedecha R, Meepathom W, Manuskiatti W. A pilot study of treatment of striae distensae with variable square pulse Erbium: YAG laser resurfacing. *J Cosmet Dermatol* 2017;16:466-70.
43. Shen J, Lu XG, Jin JJ, Wang HW. Combination of a 2940 nm Er:YAG laser with recombinant bovine basic fibroblast growth factor (rb-bFGF) and light-emitting diode-red light (LED-RL) for the treatment of striae alba: A pilot study. *J Cosmet Dermatol* 2017; doi: 10.1111/jocd.12376. [Epub ahead of print].
44. Yang YJ, Lee GY. Treatment of striae distensae with nonablative fractional laser versus ablative CO₂ fractional laser: A randomized controlled trial. *Ann Dermatol* 2011;23:481-9.
45. Guimarães PA, Haddad A, Sabino Neto M, Lage FC, Ferreira LM. Striae distensae after breast augmentation: Treatment using the nonablative fractionated 1550-nm erbium glass laser. *Plast Reconstr Surg* 2013;131:636-42.
46. Kim BJ, Lee DH, Kim MN, Song KY, Cho WI, Lee CK, *et al.* Fractional photothermolysis for the treatment of striae distensae in Asian skin. *Am J Clin Dermatol* 2008;9:33-7.
47. Sherling M, Friedman PM, Adrian R, Burns AJ, Conn H, Fitzpatrick R, *et al.* Consensus recommendations on the use of an erbium-doped 1,550-nm fractionated laser and its applications in dermatologic laser surgery. *Dermatol Surg* 2010;36:461-9.
48. Malekzad F, Shakoei S, Ayatollahi A, Hejazi S. The safety and efficacy of the 1540 nm non-ablative fractional XD probe of star lux 500 device in the treatment of striae alba: Before-after study. *J Lasers Med Sci* 2014;5:194-8.
49. Alves RO, Boin MF, Crocco EI. Striae after topical corticosteroid: Treatment with nonablative fractional laser 1540nm. *J Cosmet Laser Ther* 2015;17:143-7.
50. Tretti Clementoni M, Lavagno R. A novel 1565 nm non-ablative fractional device for stretch marks: A preliminary report. *J Cosmet Laser Ther* 2015;17:148-55.
51. Wang K, Ross N, Osley K, Sahu J, Saedi N. Evaluation of a 1540-nm and a 1410-nm nonablative fractionated laser for the treatment of striae. *Dermatol Surg* 2016;42:225-31.
52. Gokalp H. Long-term results of the treatment of pregnancy-induced striae distensae using a 1550-nm non-ablative fractional laser. *J Cosmet Laser Ther* 2017;19:378-82.
53. Naein FF, Soghrafi M. Fractional CO₂ laser as an effective modality in treatment of striae alba in skin types III and IV. *J Res Med Sci* 2012;17:928-33.
54. Naeini FF, Nikyar Z, Mokhtari F, Bahrami A. Comparison of the fractional CO₂ laser and the combined use of a pulsed dye laser with fractional CO₂ laser in striae alba treatment. *Adv Biomed Res* 2014;3:184.
55. El Taieb MA, Ibrahim AK. Fractional CO₂ laser versus intense pulsed light in treating striae distensae. *Indian J Dermatol* 2016; 61:174-80.
56. Gauglitz GG, Reinholz M, Kaudewitz P, Schaubert J, Ruzicka T. Treatment of striae distensae using an ablative erbium: YAG fractional laser versus a 585-nm pulsed-dye laser. *J Cosmet Laser Ther* 2014;16:117-9.
57. de Angelis F, Kolesnikova L, Renato F, Liguori G. Fractional nonablative 1540-nm laser treatment of striae distensae in Fitzpatrick skin types II to IV: Clinical and histological results. *Aesthet Surg J* 2011;31:411-9.
58. Lee SE, Kim JH, Lee SJ, Lee JE, Kang JM, Kim YK, *et al.* Treatment of striae distensae using an ablative 10,600-nm carbon dioxide fractional laser: A retrospective review of 27 participants. *Dermatol Surg* 2010;36:1683-90.
59. Suh DH, Chang KY, Son HC, Ryu JH, Lee SJ, Song KY. Radiofrequency and 585-nm pulsed dye laser treatment of striae distensae: A report of 37 Asian patients. *Dermatol Surg* 2007; 33:29-34.
60. Stotland M, Chapas AM, Brightman L, Sukal S, Hale E, Karen J, *et al.* The safety and efficacy of fractional photothermolysis for the correction of striae distensae. *J Drugs Dermatol* 2008;7:857-61.