

## Case Report

# Leiomyoma mimicking hypertrophic scar/keloid over the surgical incision site

Surajit Gorai<sup>1</sup>, Kinnor Das<sup>2</sup> 

<sup>1</sup>Department of Dermatology, Apollo Multispeciality Hospital, Kolkata, West Bengal, <sup>2</sup>Department of Dermatology, Apollo Clinic Silchar, Silchar, Assam, India.

### \*Corresponding author:

Surajit Gorai,  
Department of Dermatology,  
Apollo Multispeciality Hospital,  
Kolkata, West Bengal, India.

[drsurajit@drgorai.com](mailto:drsurajit@drgorai.com)

Received: 01 September 2024  
Accepted: 10 November 2024  
Epub Ahead of Print: 18 December 2024  
Published: 02 February 2026

### DOI

10.25259/JCAS\_65\_2024

### Quick Response Code:



## ABSTRACT

Following surgery, hypertrophic scars/keloid is a frequent consequence, especially in people with a hereditary propensity for scar development. Although the precise cause of hypertrophic scar development is unknown, it is believed to be caused by an excess of collagen being produced at the site of damage. There are several ways to treat hypertrophic scars, including cryotherapy, laser therapy, intralesional steroids (ILS), and surgical excision. Recurrence rates are significant, and treatment results might be uncertain. In this case report, we describe a 43-year-old male patient who had spinal decompression and fixation surgery and thereafter acquired a hypertrophic scar/keloid-like lesion that was resistant to ILS. Following a biopsy, it was discovered that the tumor was a leiomyoma, which is quite rare in this situation.

**Keywords:** Hypertrophic scar, Keloid, Leiomyoma, Surgical incision

## INTRODUCTION

Hypertrophic scar or keloid can happen over surgical or non-surgical trauma sites in predisposed individuals. Intralesional steroids (ILSs) are a standard therapy for that condition. We present a case of a patient with a hypertrophic scar over the back that developed after spine surgery, which, upon receiving ILS, progressed to form a keloid.

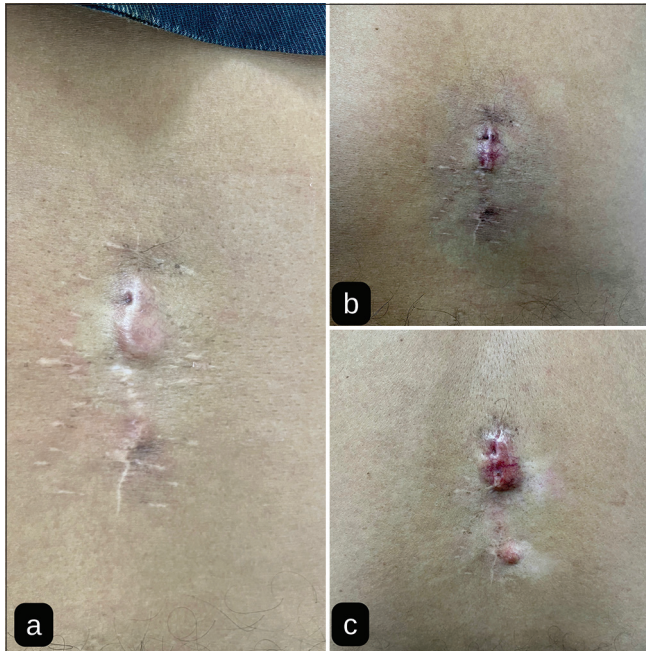
## CASE REPORT

The patient, a 43-year-old male, presented with a firm, elongated, and mildly erythematous plaque at the site of a previous spinal decompression and fixation surgery 2 years back. The patient did not have any family history or similar lesions elsewhere in the body. The lesion had grown progressively over the past year and was causing itching, mild pain, and discomfort. The patient had previously undergone treatment with three sessions of ILSs in 1 month interval, but the lesion did not respond to this therapy. Thinking it as hypertrophic scar one more session of ILS given after 2 months when patient came to me. Despite treatment, the lesion continued to enlarge and developed into a keloidal lesions within 2 months [Figure 1]. Hence, it was decided to do a biopsy to confirm the diagnosis.

An histopathology examination showed bundles of spindle-shaped cells with elongated, cigar-shaped nuclei, arranged in a whorled pattern. These cells had a smooth appearance and a moderate

This is an open-access article distributed under the terms of the Creative Commons Attribution-Non Commercial-Share Alike 4.0 License, which allows others to remix, transform, and build upon the work non-commercially, as long as the author is credited and the new creations are licensed under the identical terms.

©2026 Published by Scientific Scholar on behalf of Journal of Cutaneous and Aesthetic Surgery



**Figure 1:** (a) Lower back showing a midline linear keloid like mass, (b) Lesion after first intralesional steroid (ILS) injection, and (c) Lesion after second ILS injection.

amount of eosinophilic cytoplasm. The finding was consistent with a leiomyoma. For confirmation, immunohistochemistry was done with desmin, smooth muscle actin (SMA), and Kiel-67 (Ki-67 Stain) and it was confirmatory [Figure 2]. Leiomyomas are benign tumors that arise from smooth muscle cells and are usually found in the uterus or gastrointestinal tract. Leiomyomas are rare in the skin and subcutaneous tissue, particularly following trauma or surgery.

### Treatment

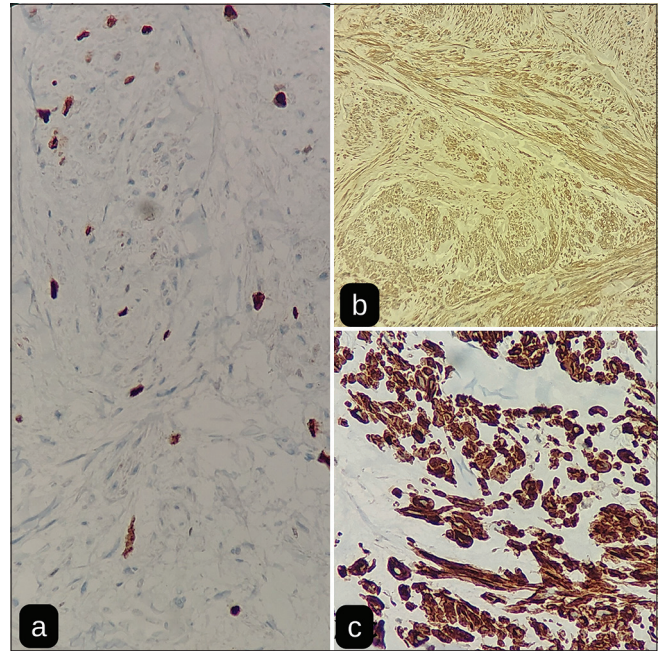
After the diagnosis of leiomyoma was confirmed, the patient underwent surgical excision of the lesion. The procedure was performed under local anesthesia, and the lesion was completely excised. The wound was closed with sutures.

### Outcome

The patient experienced an uneventful post-operative recovery, with no complications or recurrence of the lesion. The histopathological analysis of the excised lesion confirmed the diagnosis of leiomyoma, and the patient was advised to follow-up with regular check-ups to monitor for any signs of recurrence.

## DISCUSSION

Hypertrophic scars/keloid is a frequent post-operative consequence, and treatment results might vary. A biopsy



**Figure 2:** (a) Kiel-67 (Ki-67 Stain) stain, 40x. (b) Smooth muscle actin (SMA) stain, 10x and (c) Desmin stain, 40x.

may be required to rule out other underlying reasons when standard treatments, such as ILS, are ineffective in treating hypertrophic scars.<sup>1</sup> Leiomyoma is a benign tumor that develops from smooth muscle cells. These tumors may develop in the skin, uterus, and other organs. Leiomyomas are normally slow-growing and asymptomatic, although depending on the organ or tissue they impact, their size and location may result in symptoms. Leiomyomas in the uterus, sometimes referred to as uterine fibroids, are the most prevalent benign tumors in women of reproductive age. They may result in various symptoms such as infertility, painful pelvis, and excessive menstrual flow. Leiomyomas in the skin appear as firm, well-defined nodules that are often asymptomatic. Leiomyoma is diagnosed based on clinical symptoms and imaging tests such as magnetic resonance imaging or ultrasound. Histopathological analysis and biopsy are gold standard investigations. Depending on the location, size, and severity of the tumor, there are many treatment options for leiomyomas. A surgical excision of the tumor or hormonal treatments may be advised in certain situations, while observation and monitoring may be suitable in others. Although leiomyomas are normally benign, there have been a few recorded occurrences of leiomyosarcoma, a malignant version of the condition. Within 15 years, up to 50% of cases may recur even after complete excision. In situations where surgical intervention is not feasible or is declined by the patient, alternatives such as nifedipine or

nitroglycerin may be considered. Therefore, an accurate diagnosis and appropriate treatment rely heavily on detailed histological evaluation.<sup>2-4</sup>

## CONCLUSION

Hypertrophic scars/keloid are consequences of surgery, trauma, infection, or sometimes spontaneous development in predisposed individuals. Histopathological examinations may be required to rule out other differential diagnosis when traditional therapy fails to improve hypertrophic scars. This instance emphasizes the need for awareness of leiomyomas, which are few and far between tumors that may develop in the skin and subcutaneous tissue after trauma or surgery. Additional study is required to better understand the pathophysiology of leiomyomas and to provide more potent therapy choices.

**Authors' contributions:** Dr. Surajit Gorai: Conceptualization, clinical investigation, writing - Original draft. Dr. Kinnor Das: Literature review, writing - review and editing. Both authors reviewed and approved the final manuscript.

**Ethical approval:** The Institutional Review Board approval is not required.

**Declaration of patient consent:** The authors certify that they have obtained all appropriate patient consent forms. In the form, the patients have given their consent for their images and other clinical information to be reported in the journal. The patients understand

that their names and initials will not be published and due efforts will be made to conceal their identity, but anonymity cannot be guaranteed.

**Financial support and sponsorship:** Nil.

**Conflicts of interest:** There are no conflicts of interest.

**Use of artificial intelligence (AI)-assisted technology for manuscript preparation:** The authors confirm that there was no use of artificial intelligence (AI)-assisted technology for assisting in the writing or editing of the manuscript and no images were manipulated using AI.

## REFERENCES

1. Urioste SS, Arndt KA, Dover JS. Keloids and hypertrophic scars: Review and treatment strategies. *Semin Cutan Med Surg* 1999;18:159-71.
2. Bennett CN, Mammino JJ. Cutaneous leiomyomas. In: *StatPearls*. Treasure Island, FL: StatPearls Publishing; 2023. Available from: <http://www.ncbi.nlm.nih.gov/books/NBK482166> [Last accessed on 2023 May 07].
3. Ghanadan A, Abbasi A, Hesari KK. Cutaneous leiomyoma: Novel histologic findings for classification and diagnosis. *Acta Med Iran* 2013;51:19-24.
4. Arleo EK, Schwartz PE, Hui P, McCarthy S. Review of leiomyoma variants. *Am J Roentgenol* 2015;205:912-21.

**How cite this article:** Gorai S, Das K. Leiomyoma mimicking hypertrophic scar/keloid over the surgical incision site. *J Cutan Aesthet Surg*. 2026;19:S39-41. doi: 10.25259/JCAS\_65\_2024