

Innovations

A customized syringe for separating ingrown toe nail from the gutter

Muhammed Mukhtar¹, Nadia Mukhtar¹

¹Mukhtar Skin Centre, KMCH Road, Katihar, Bihar, India.

*Corresponding author:

Muhammed Mukhtar,
Mukhtar Skin Centre, KMCH
Road, Katihar, Bihar, India.

drmmukhtar20@gmail.com

Accepted: 15 June 2022
Epub Ahead of Print: 02 December 2022
Published: 29 August 2024

DOI

10.4103/JCAS.JCAS_48_22

Quick Response Code:



ABSTRACT

Ingrown toenails is a painful foot problem seen in primary care among young men. To provide immediate pain relief, some types of splints are placed in the gutter to separate it from the ingrown lateral nail. There are time-consuming and effort-intensive procedures that use available nail separators and elevators to separate the nail plate. Here, the hub of the syringe is cut obliquely to create a beveled or slant edge to create a custom nail separator which is a useful device for the easy and less painful separation of the ingrown nail plate from its gutter, which is an important stage of nail splinting.

Keywords: Cyanoacrylate glue, Disposable syringe, Ingrown nail, Nail gutter, Nail plate, Nail separator, Needle hub

PROBLEM STATEMENT

Ingrown toenails account for roughly 20% of all foot problems seen in primary care among young men.¹ To provide an immediate pain relief, some types of splints are placed in the gutter to separate it from the ingrown lateral nail. A variety of noninvasive techniques have been used to treat mild-to-moderate ingrown nails.^{2,3} However, these are time-consuming and effort-intensive

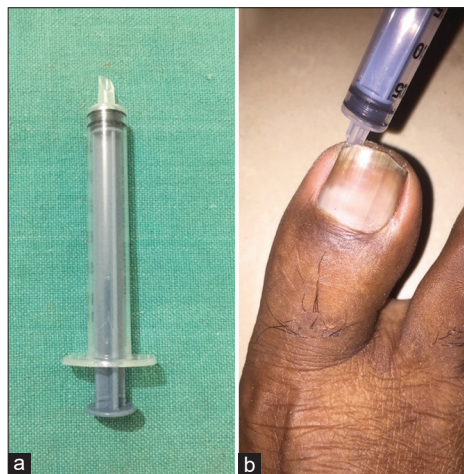


Figure 1: (a) and (b) A customized needle hub used for separating the lateral nail plate from its gutter.

This is an open-access article distributed under the terms of the Creative Commons Attribution-Non Commercial-Share Alike 4.0 License, which allows others to remix, transform, and build upon the work non-commercially, as long as the author is credited and the new creations are licensed under the identical terms.

©2024 Published by Scientific Scholar on behalf of Journal of Cutaneous and Aesthetic Surgery

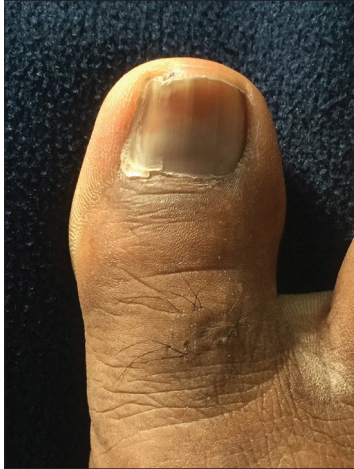

Figure 2: The ingrown nail splinted with cyanoacrylate glue.

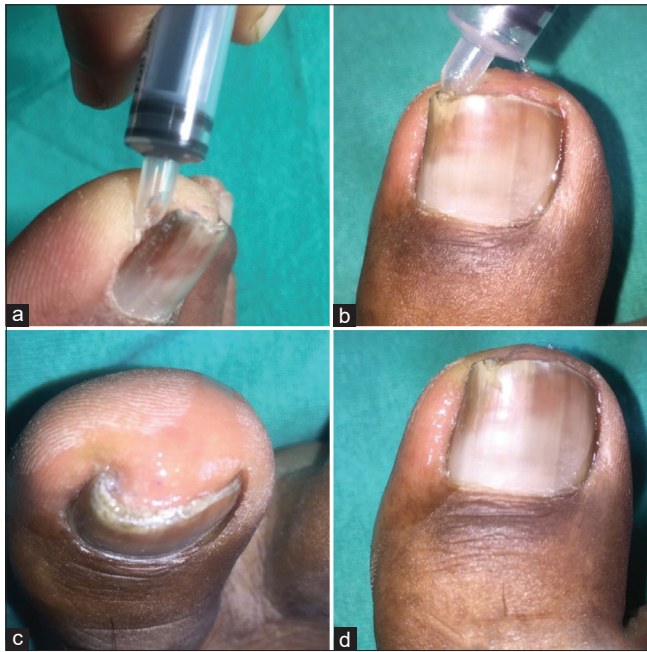

Figure 3: (a-d) The procedure to use the syringe for separating the distal part of ingrown nail plate from its gutter, which is helpful in chemical splinting the nail with cyanoacrylate glue.

procedures that use available nail separators and elevators to separate the nail plate. In this article, we introduce a new disposable device for separating the nail plate during ingrown nail splinting.

RECOMMENDED SOLUTION

We used a disposable syringe to separate the distal part of the ingrown nail plate from its gutter. The needle hub

of the syringe is cut to create a customized nail separator. The hub of the syringe is cut obliquely to create a beveled or slant edge to create a custom nail separator [Figure 1a]. Then a beveled hub is inserted into the nail gutter along the nail plate through the hyponychium route, avoiding contact with the most painful distal part of the gutter. After reaching the gutter, the syringe applies outward pressure to easily separate the ingrown nail plate from its gutter [Figure 1b]. The cyanoacrylate glue is then poured into the gutter, hardening it and blunting the nail spicule and edge of the nail plate. As a result, the effective pressure of the nail on the soft gutter is reduced. Pressure is defined as force per unit area ($P = F/A$). Within 5–10 min of the glue curing, the lesions became painless or less painful [Figure 2]. After about 2–3 months, the pain returns only after the excessive trimming of the nail plate and the expulsion of cured glue from the nail and the gutter. For a longer period of remission, we must take general care of excess nail trimming, trauma, and moisture in the gutter. Even if it occurs again, repeat the same procedure, which is simple to carry out. As a result, the customized syringe hub is a useful device for the easy and less-painful separation of the ingrown nail plate from its gutter, which is an important stage of the chemical nail splinting [Figure 3a-d].

Authors' contributions

All the authors contributed to the research study. Muhammed Mukhtar: Concepts, Design, Definition of intellectual content, Literature search, Manuscript preparation, Manuscript Editing, and Manuscript review. Nadia Mukhtar: Concepts, Design, Definition of intellectual content, Literature search, Manuscript preparation, Manuscript Editing, and Manuscript review.

Declaration of patient consent

The authors certify that they have obtained all appropriate patient consent forms. In the form the patient(s) has/have given his/her/their consent for his/her/their images and other clinical information to be reported in the journal. The patients understand that their names and initials will not be published and due efforts will be made to conceal their identity, but anonymity cannot be guaranteed.

Financial support and sponsorship

Nil.

Conflicts of interest

There are no conflicts of interest.

REFERENCES

1. Mayeaux EJ Jr, Carter C, Murphy TE. Ingrown toenail management. *Am Fam Physician* 2019;100:158-64.
2. Mukhtar M. A simplified chemical technique of splinting mild to moderate ingrown toenail (grade 1 and 2). *Mod Care J* 2021;18:e113033.
3. Chabchoub I, Litaiem N. Ingrown toenails. In: StatPearls. Treasure Island (FL): StatPearls publishing; 2022.

How to cite this article: Mukhtar M, Mukhtar N. A customized syringe for separating ingrown toe nail from the gutter. *J Cutan Aesthet Surg.* 2024;17:259-61. doi: 10.4103/JCAS.JCAS_48_22